IMMEDIATE DENTOALVEOLAR RESTORATION FOR THE TREATMENT OF TYPE II AND TYPE III EXTRACTION SOCKETS USING TRIPLE GRAFT FROM MAXILLARY TUBEROSITY: A CASE SERIES.

JOSÉ C. MARTINS DA ROSA, ARIÁDENE C. PÉRTILE DE OLIVEIRA ROSA, LUIS A. VIOLÍN DIAS PEREIRA.

José Carlos Martins da Rosa. PhD in Oral Implantology, São Leopoldo Mandic Dental Research Center, Campinas, São Paulo, Brazil.

Ariádene Cristina Pértile de Oliveira Rosa. PhD in Oral Implantology, São Leopoldo Mandic Dental Research Center, Campinas, São Paulo, Brazil

Luis Antonio Violín Dias Pereira. Professor of Department of Biochemistry and Tissue Biology, State University of Campinas (UNICAMP), Institute of Biology, Campinas, São Paulo, Brazil.

Correspondence to:

José Carlos Martins da Rosa
josecarlos@rosaodontologia.com.br

SUMMARY

Introduction
Immediate implant placement in compromised sockets is challenging. The three-dimensional implant position, buccal bone wall quality, and regeneration of soft-tissue contours are key factors for long-term outcomes. Here, we present three cases in which immediate dentoalveolar restoration (IDR) with a triple graft (TG) was used for the treatment of Type II and Type III extraction sockets. IDR-TG consists of immediate implantation; harvesting of a single-piece TG comprising connective tissue and cortical and cancellous bone from the maxillary tuberosity (MT); and immediate provisionalization in a single procedure.

Case presentation
One case with Type II and two cases with Type III extraction sockets in the maxillary anterior zone showed bone loss and extremely thin periodontal biotypes. Cases 2 and 3 showed socket infection along with gingival recession. IDR-TG was performed in all cases, with 5–8 years follow-up to demonstrate the stability of the bone walls and soft-tissue (gingival margin and papillae) contour.

Discussion
The main advantages of IDR-TG use observed in this case series are the reversal of severe buccal bone loss, improved gingival thickness, and compensation of gingival recession in a single procedure, which reduces overall costs and treatment times. These three cases exemplify the method's clinical and tomographic effectiveness in the achievement of soft- and hard-tissue stability in extraction sockets.

Conclusion
IDR-TG yielded excellent long-term results in the three cases reported here and should be considered for the treatment of Type III extraction sockets.


José C. Martins da Rosa


A. C. Pértile de Oliveira Rosa


Luis A. Violín Dias Pereira

INTRODUCTION

IMMEDIATE IMPLANT PLACEMENT after condemned tooth extraction may be challenging due to the presence of bone defects, infection, and/or inflammation. The preservation or creation of harmonious soft-tissue contours in the peri-implant mucosa and adequate bone support are the key for the achieving favorable esthetic outcomes after esthetic-zone implant treatment (Rosa et al. 2009; Huynh-Ba et al. 2010).

Several surgical alternatives for post-extraction bone and soft-tissue augmentation in compromised sockets have been described (Elian et al. 2007; Cosyn et al. 2011; Schneider et al. 2011; Buser et al. 2013, 2017; Kan et al. 2018). However, these procedures may require more than one tissue graft type and/or guided bone regeneration, and they entail long rehabilitation periods and high costs.

In 2007, Elian et al. proposed a classification of alveolar defects, improved in 2015 by Chu et al., which were taken into account in this article. Type II, subclassification IIC, and Type III defects present with a greater degree of difficulty in therapy and should be approached with caution, especially in the esthetic zone (Elian et al. 2007; Chu et al. 2015). In addition to the effects of bone loss and soft-tissue recession on the treatment of extraction sockets, we have considered the effects of gingival recession, periapical lesions, infection, severe bone loss around the condemned tooth, and the periodontal biotype (Rosa et al. 2019).

In 2006, our group introduced immediate dentoalveolar restoration (IDR), a regeneration technique used for the treatment of Type II sockets, regardless of bone defect extent. IDR consists of immediate implant placement with the placement of a cortico-cancellous block graft harvested from the maxillary tuberosity (MT) (Rosa et al. 2013, 2014d). Tooth extraction and rehabilitation are achieved with this single procedure, summarized as (Rosa et al. 2013, 2014d):

1. Minimally invasive tooth extraction and socket curettage and cleaning, avoiding damage to the remaining tissue
2. Flapless surgery at the recipient site with an intrasulcular incision for extraction
3. Implant placement 3 mm apical to the gingival margin (or the cementoenamel junction of the contralateral tooth in cases of gingival recession), with the selection of an implant diameter enabling preservation of a 3-mm socket gap (between the implant and buccal bone wall, or internal surface of the buccal soft tissue when the buccal bone wall is absent) (Rosa et al. 2016)
4. Implant positioning, primarily by guided surgery, with direction toward the palatine bone wall to obtain primary stability (insertion torque ≥30 Ncm)
5. Preservation of the alveolar ridge dimensions with a particulate bone graft harvested from the MT positioned in the 3-mm socket gap (for intact sockets), and a cortico-cancellous block from the MT as a biological barrier when the bone wall is absent
6. Immediate temporary crown placement and appropriate emergence profile creation
7. Immediate non-occlusal loading (provisionalization).

Postoperatively, patient monitoring every 2 days for the first 2 weeks and every 15 days for the next 3 months is recommended. This protocol yielded satisfactory, predictable esthetic outcomes in a prospective case series (Rosa et al. 2016). The most challenging aspects of its technical application are related to accurate socket defect diagnosis and graft adaptation in the recipient site, as the procedure is flapless. Prototyping may facilitate the procedure and increase precision (Rosa et al. 2017).

In 2009, our team introduced the use of a triple graft (TG), formed by adding a layer of connective tissue to the cortico-cancellous block and particulate bone, for IDR. IDR-TG is indicated for the treatment of Type III sockets with extremely thin periodontal biotypes or severe buccal bone wall damage in combination with gingival recession (Rosa et al. 2009). It enables proper implant rehabilitation in a fresh compromised extraction socket with alveolar bone and soft-tissue defects and provides significant gains in esthetic outcomes, with gingival architecture maintenance or improvement (Rosa et al. 2014a; Rosa and Pereira 2019). We describe three cases illustrating the favorable clinical outcomes achieved with IDR-TG, including long-term gingival topography and bone stability, as observed by cone-beam computed tomography (CBCT).

CASE 1

1. The patient's problem
A 33-year-old female presented with a compromised maxillary right central incisor, severe bone loss, and a thin periodontal biotype.

2. Diagnosis
Clinical inspection revealed an extremely thin gingival biotype (Figure 1) and CBCT confirmed total buccal bone wall loss, showing a Type IIC alveolar defect (Figure 2).

3. Aim of the treatment
The main treatment aims were to restore the buccal wall and increase gingival thickness.

Figure 1.
Clinical evaluation of case 1 revealed a condemned maxillary right central incisor with total loss of the buccal wall and extremely thin periodontal biotype without gingival recession. The periodontal pocket depth was 10 mm.

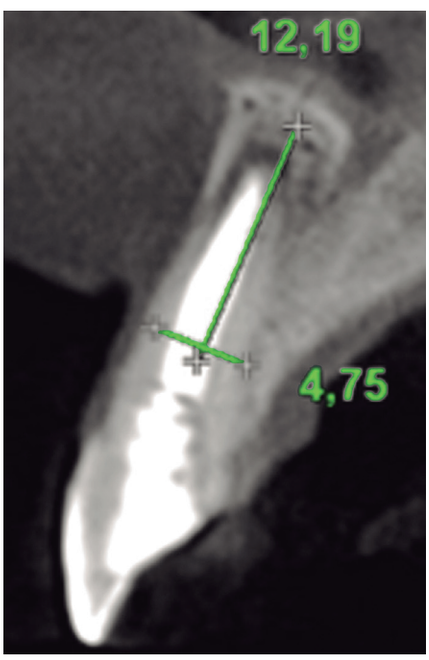

Figure 2.
CBCT confirmed the total loss of the buccal bone wall in case 1.

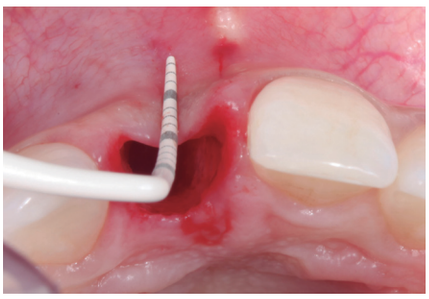

Figure 3.
After tooth extraction in case 1, loss of the buccal wall was confirmed clinically.

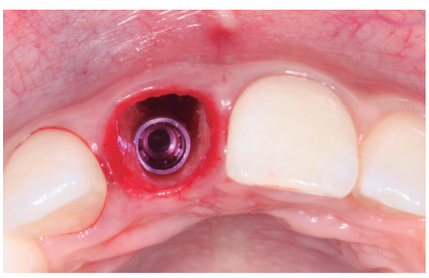

Figure 4.
In case 1, the implant was anchored to the remaining palatal bone in the 3D position favoring the construction of the screw-type provisional crown. As the dimension of the buccal–palatal socket was 7 mm, a 4-mm-diameter implant was selected to allow a 3-mm gap on the buccal aspect.

4. Treatment plan

Minimally invasive tooth extraction and socket curettage and cleaning were followed by immediate implant placement in the three-dimensionally (3D) correct position to achieve primary stability (insertion torque ≥30 Ncm), with a gap of about 3 mm left on the buccal aspect. A screw-type provisional crown with an ideal critical and subcritical emergence profile contour, providing space for appropriate graft accommodation, was fabricated. The buccal bone defect was repaired and soft-tissue thickness was improved using a TG harvested from the MT (Figures 3, 4, 5, 6 and 7).

For TG harvest, a mucoperiosteal incision was made along the distal contour of the second molar, approximately 3 mm from its distal aspect. Two vertical mucoperiosteal releasing incisions were then made in the posterior direction, reproducing the defect shape. The donor-site flap was then divided starting at the buccal line angle, with the blade then directed to the posterior-most portion of the releasing incisions, with retention of 1–2 mm connective-tissue thickness to cover t¬he bone. A straight IDR chisel (Schwert, Seitingen-Oberflacht, Germany) was inserted along the releasing incisions to define the bone fracture line. The chisel was initially positioned perpendicular to the bone structure on the incision line surrounding the distal part of the second molar. After about 3 mm insertion with the aid of a surgical hammer, its angulation was changed to parallel the outer connective-tissue surface (Figure 8). The chisel was deepened gradually to the distal limit of the releasing incisions to obtain a uniform bone/gingival graft. The bone was fractured, and an incision was made in the distal portion of the connective tissue to remove the TG in a single piece, with care taken to maintain an epithelial pedicle to ensure better nutrition for the donor-site flap. A particulate bone graft was harvested from the same area to fill the gap between the marrow portion of the TG and the implant surface. The donor site was then closed with single interrupted 6-0 sutures.

To facilitate TG adaptation in the recipient site, which allows for better reconstruction and accelerates graft incorporation, the graft was shaped to fit the bone and soft-tissue defect. It was inserted between the inner soft tissue and the buccal aspect of the implant, with maintenance of a biological distance of 1 mm above the level of the implant platform, and ensuring placement of its connective-tissue portion 2 mm above the bone graft area at the level of the contralateral gingival margin. The TG was stabilized by suturing its connective-tissue portion to the gingival flap. The residual gaps were filled with the particulate cancellous bone harvested from the MT. A provisional restoration was performed. An appropriate anatomical contour of the prosthetic emergence profile, mandatory to guide soft-tissue healing, was created. The provisional crown was placed immediately and adjusted out of occlusion. Definitive restoration was performed 3 months postoperatively (Figures 9 and 10).

5. Prognosis

The patient was followed clinically for 5 years. The soft-tissue contour (gingival margin and papillae) remained stable (Figure 11).

Figure 5.
The TG (connective tissue, and cortical and cancellous bone in a single piece) harvested from the MT was placed in the buccal defect site to repair the hard- and soft-tissue damage in case 1.

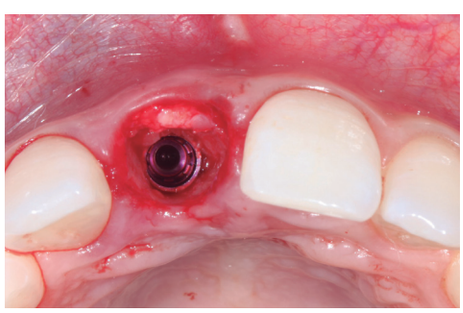

Figure 6.
Occlusal view of case 1 showing the 3-mm buccal gap filled with the TG and particulate bone graft harvested from the MT.

Figure 8.
A screw-type provisional crown with an adequate emergence profile enabling proper tissue accommodation was manufactured using the case 1 patient's crown.

Figure 9.
The soft tissue had healed and maintained the appropriate position at 3 months postoperatively in case 1.

Figure 11.
Stability of the soft-tissue contour, namely the gingival margin and papillae, at 5 years postoperatively in case 1.

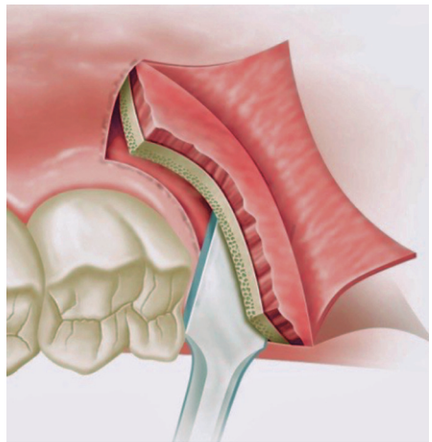

Figure 7.
The triple graft is removed with a straight chisel. First, the chisel is positioned perpendicular to the incision line. After a slight deepening with the help of a hammer, its angle is changed to be parallel to the soft-tissue surface. Then, the three graft layers (connective tissue, cortical and spongy bone) can be seen. Reproduced from Rosa et al. 2014, with authorization.

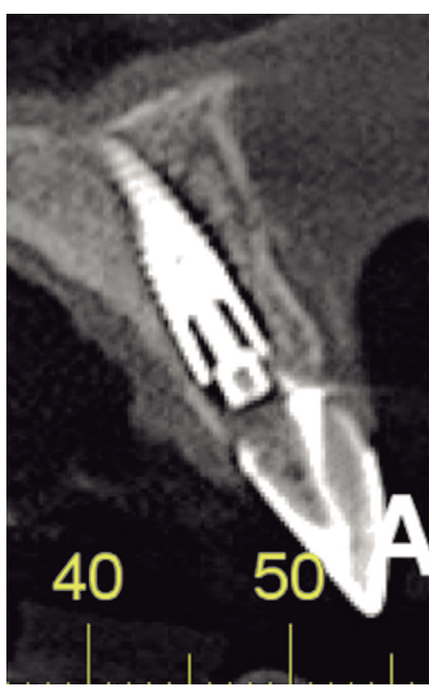

Figure 10.
Soft-tissue CBCT image of case 1 after 4 months showing incorporation of the bone graft and improvement of soft-tissue thickness.

Figure 12.
In case 2, the maxillary right canine had been lost, with about 2.0 mm gingival recession and a fistula.

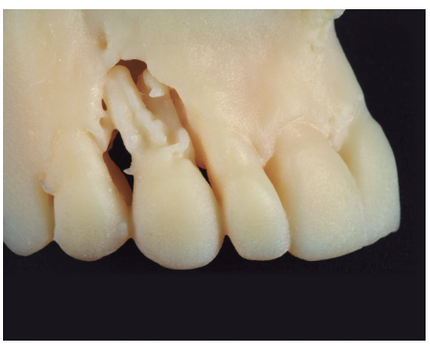

Figure 13.
3D prototyping showed the buccal bone wall defect in case 2; total loss of the buccal bone wall beyond the limits of the root can be seen.

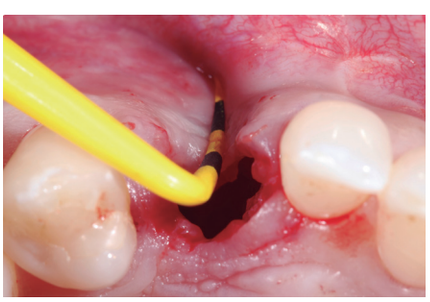

Figure 14.
After tooth extraction in case 2, the soft tissue was collapsed due to the absence of the buccal bone wall.

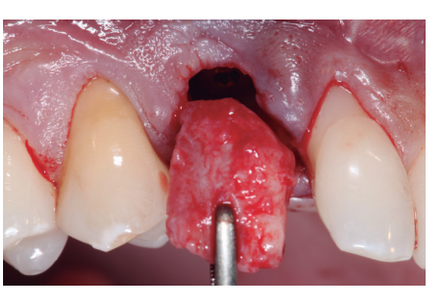

Figure 15.
In case 2, the TG harvested from the MT was inserted into the buccal defect site to repair hard- and soft-tissue damage, after implant insertion and particulate bone filling.

CASE 2

1. The patient's problem
A 28-year-old male presented with a periodontally compromised maxillary right canine associated with an abscess, fistula, severe bone loss, gingival recession, and a thin periodontal biotype (Figure 12).

2. Diagnosis
On clinical inspection, the buccal probing depth was approximately 8 mm. The alveolar defect was Type III. Soft-tissue CBCT confirmed total buccal wall loss beyond the root apex of the affected tooth. A 3D image showed the extent of the bone defect. Prototyping enabled measurement of the buccal aspect of the defect in the coronoapical and mesiodistal directions (9 and 7 mm, respectively) (Figure 13).

3. Aim of the treatment
The main treatment aims were to restore the buccal wall, improve gingival thickness, and compensate the gingival recession.

4. Treatment plan
The patient was prescribed antibiotics for 5 days preoperatively and 7 days postoperatively due to surgical area contamination. He was treated as described in case 1 (Figures 14, 15, 16, 17 and 18).

5. Prognosis
Clinical evaluation at 6 years postoperatively showed stability of the soft-tissue volume, gingival margin, and papillae positioning (Figure 19). CBCT showed complete restoration of the buccal bone wall (Figure 20).

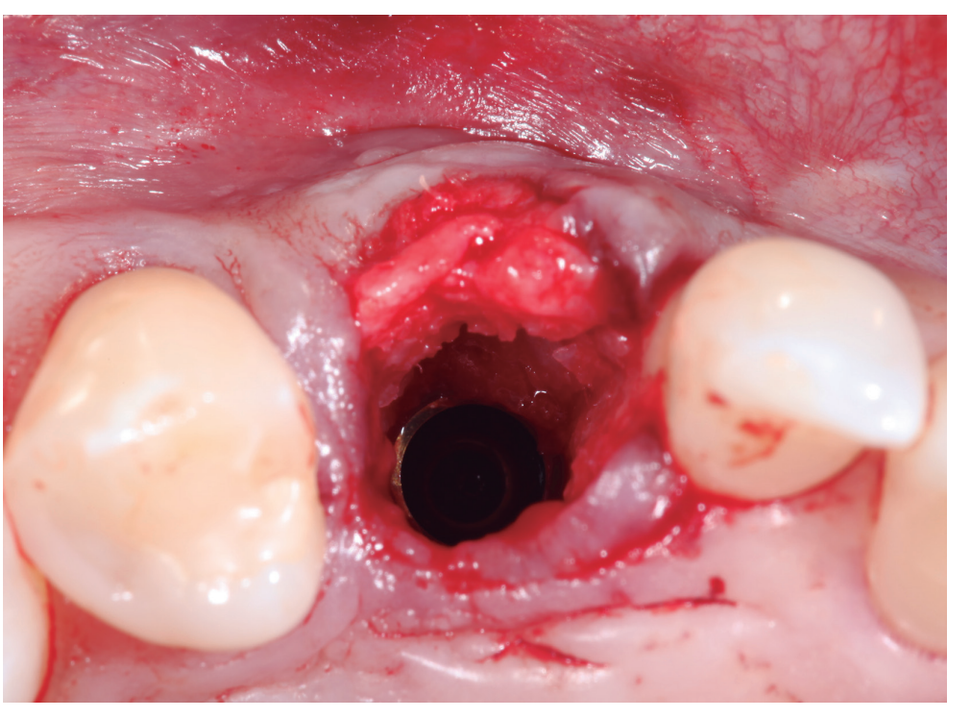

Figure 16.
Occlusal view of case 2 showing the 3 mm gap filled with the TG and cancellous particulate bone graft harvested from the MT.

Figure 17.
A screw-type provisional crown with an emergence profile enabling proper TG accommodation was inserted in case 2. Two millimeters of the connective tissue of the TG was left exposed to improve the coronal gingival margin. This tissue was sutured using 6-0 mononylon.

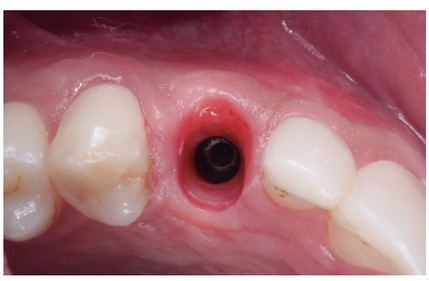

Figure 18.
The soft tissue had healed and maintained the appropriate position at 3 months postoperatively.

Figure 19.
Case 2 showed stability of the soft tissue at 6 years postoperatively.

Figure 20.
CBCT performed 6 years postoperatively in case 2 revealed stability of the buccal wall thickness and height.

Figure 21.
In case 3, the maxillary right central incisor region showed about 3.0 mm gingival recession, the presence of an abscess, and poor soft-tissue quality.

Figure 22.
CBCT showed total absence of the buccal bone wall in case 3.

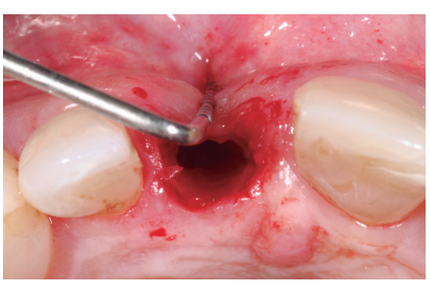

Figure 23.
In case 3, the soft tissue had collapsed after tooth extraction due to the absence of the buccal bone wall.

CASE 3

1. The patient's problem
A 49-year-old male presented with a compromised maxillary right central incisor associated with severe bone loss, an abscess, fistula, gingival recession, and an extremely thin periodontal biotype.

2. Diagnosis
On clinical inspection, the buccal probing depth was approximately 10 mm (Figure 21). CBCT confirmed total buccal bone wall loss beyond the root apex of the affected tooth (Figure 22).

3. Aim of the treatment
The main treatment aims were to restore the buccal bone wall, improve gingival thickness, and compensate the gingival recession.

4. Treatment plan
The patient was treated as in cases 1 and 2, with the following differences. Given the degree of gingival recession, four incisions were made in the gingival papillae area; two horizontal incisions in the area corresponding to the cementoenamel junction of the adjacent tooth, followed by two divergent incisions corresponding to the gingival recession pattern for coronal repositioning of the gingival tissue (Figures 23 and 24). The connective-tissue portion of the graft was then stabilized up to the level of the repositioned gingival margin (Figures 25, 26 and 27), as appropriate in such cases with 3–4 mm gingival recession. Other aspects of graft and provisional crown placement were as described for case 1 (Figure 28). After 3 months, a final ceramic crown was fabricated and placed (Figure 29).

5. Prognosis
Clinical evaluation at 8 years postoperatively showed soft-tissue (gingival margin and papillae) stability and maintenance of the anatomical contour of the gingival architecture (Figure 30). CBCT showed complete restoration of the buccal bone wall (Figure 31).

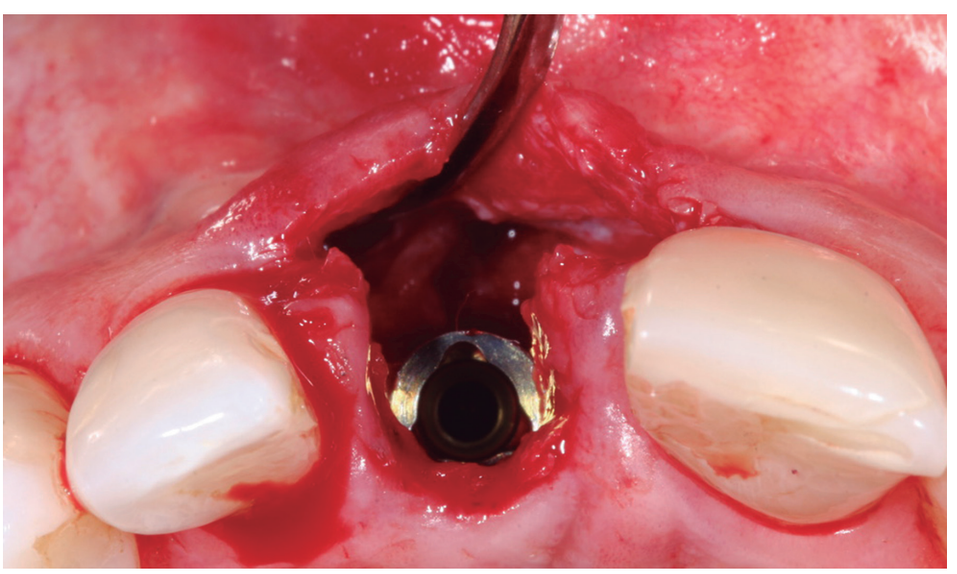

Figure 24.
The implant was installed with palatine anchoring in case 3. Four small incisions in the gingival papillae area were performed: two horizontal incisions, followed by two divergent incisions corresponding to the gingival recession pattern. The pedicles between the two incisions were removed.

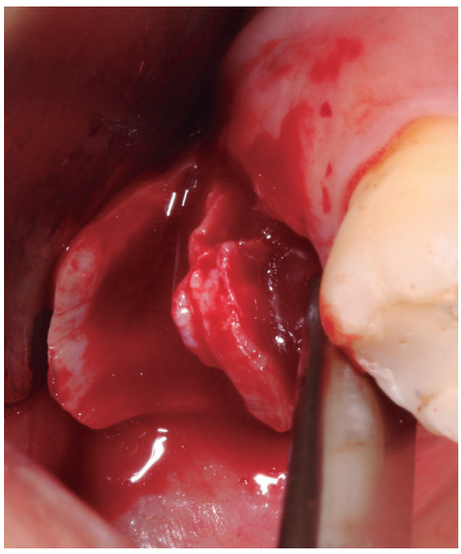

Figure 25.
In case 3, the TG was harvested from the MT using a chisel.

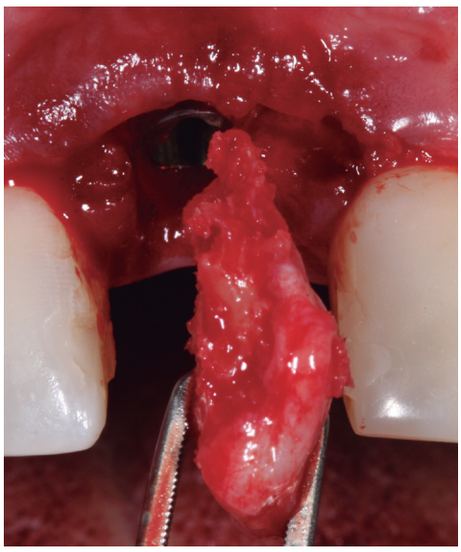

Figure 26.
The TG in case 3 was remodeled according to the defect shape and size.

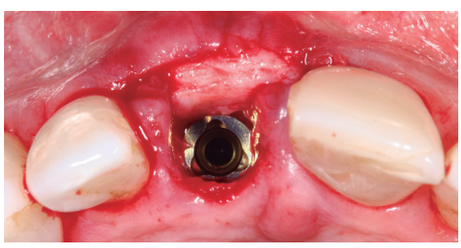

Figure 27.
It was positioned in the recipient site with the connective tissue portion turned to the gingival mucosa and the cancellous bone portion turned to the implant. The gap was filled with the particulate bone graft.

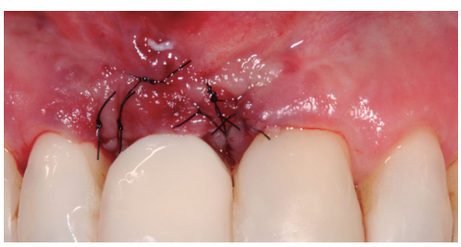

Figure 28.
A screw-type provisional crown with an emergence profile that enabled TG accommodation inserted in case 3. The graft was stabilized by suturing of its connective tissue portion to the gingival flap in the recipient area. Simple sutures were placed in the mesial and distal papillae regions.

Figure 29.
The soft tissue had healed and maintained its appropriate position, with remarkable volume on the buccal aspect, at 3 months postoperatively in case 3.

Figure 30.
Case 3 showed stability of the soft-tissue contour (gingival margin and papillae positions) at 8 years postoperatively.

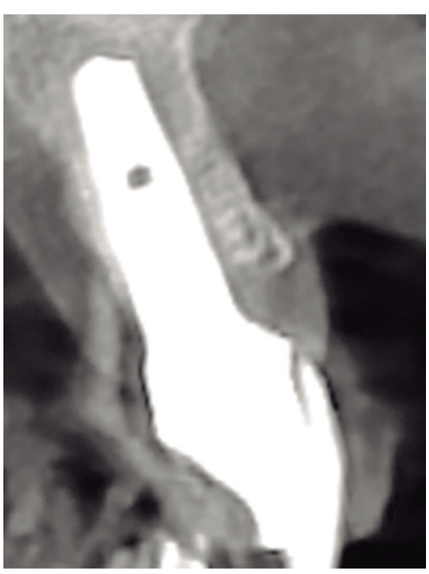

Figure 31.
CBCT perfomed 8 years postoperatively in case 3 revealed stability of the buccal bone wall thickness and height.

DISCUSSION

NUMEROUS SURGICAL PROCEDURES FOR EXTRACTION SOCKET TREATMENT with immediate implant placement have been described (Elian et al. 2007; Cosyn et al. 2011; Schneider et al. 2011; Buser et al. 2013, 2017; Kan et al. 2018). Surgical access to extraction sockets has been obtained with full flaps (Waki and Kan 2016) and no flap (Frizzera et al. 2019). To address buccal bone-plate deficiency and fill residual defects, autogenous bone chip grafts (Noelken et al. 2011), particulate deproteinized bovine bone mineral (DBBM) with and without autogenous bone (Kan et al. 2007; Tripodakis et al. 2016), platelet concentrates with allogeneic mineral bone (Norero and Ibanez 2018), DBBM mini-blocks with collagen (Albiero et al. 2014; Assaf et al. 2017), and bovine bone mineral containing 10% porcine collagen placed between the membrane and dental implant with a soft-tissue graft (Fizzera et al. 2019) have been used. All graft types yield satisfactory esthetic results, with some limitations.

IDR is minimally invasive, performed with autogenous bone and soft-tissue grafts harvested from a single site; the lack of xenogeneic or allogeneic graft or membrane requirement reduces the overall treatment cost and the possibility of infection or rejection. It has been shown clinically and tomographically to effectively achieve soft-tissue and bone stability, thereby re-establishing long-term esthetics and function for Types II and III extraction sockets (Rosa et al. 2014c, 2016).

The TG from the MT is ideal for bone and soft-tissue regeneration, as it provides a natural scaffold filled with cells and growth factors. For this reason, IDR-TG is considered to be a form of tissue transplantation (Rosa et al. 2013; Martins Jr. et al. 2017; Montanaro et al. 2019). The long-term success of IDR can be attributed in part to the MT graft's structural and biological characteristics, and proper manipulation and adaptation to the recipient site (Rosa et al. 2014a, 2014b, 2016, 2018).

CONCLUSIONS

CLINICALLY AND TOMOGRAPHICALLY, IDR-TG provided hard- and soft-tissue gains, with satisfactory esthetic and functional outcomes, in cases with Types IIC and III extraction sockets. The use of a single-piece TG harvested from the MT should be considered for alveolar ridge preservation and reconstruction, as it allows for soft- and hard-tissue integration with a single approach. IDR-TG is a feasible, low-cost solution that minimizes soft- and hard-tissue collapse and dimensional loss following single-rooted tooth extraction. Even though it is a sensitive technique and requires experience and training, when properly indicated and performed, this approach has a high success rate.

CLINICAL RELEVANCE

IN CLINICAL CASES CHARACTERIZED BY TYPE IIC with thin periodontal biotype, and Type III extraction sockets with thin or thick periodontal biotypes in combination with ≤4 mm gingival recession or infection, the use of IDR with a TG harvested from the MT for the regeneration of hard- and soft-tissue damage in the extraction socket yields clinically and tomographically satisfactory long-term outcomes. When indicated, tissue transplant with a TG (a single piece composed of connective tissue and cortical and cancellous bone) improves graft vascularization and the recovery of gingival recession and bone loss.

BIBLIOGRAPHICAL REFERENCES

Albiero AM, Benato R, Degidi M. (2014) Buccal plate regeneration with immediate postextraction implant placement and restoration: Case reports. *International Journal of Periodontics & Restorative Dentistry* **34**, e67-e72.

Assaf JH, Assaf DD, Antoniazzi RP, Osorio LB, Franca FM. (2017) Correction of buccal dehiscence during immediate implant placement using the flapless technique: A tomographic evaluation. *Journal of Periodontology* **88**, 173-180.

Buser D, Chappuis V, Bornstein MM, Wittneben JG, Frei M, Belser UC. (2013) Long-term stability of contour augmentation with early implant placement following single tooth extraction in the esthetic zone: A prospective, cross-sectional study in 41 patients with a 5-to 9-year follow-up. *Journal of Periodontology* **84**, 1517-1527.

Buser D, Chappuis V, Belser UC, Chen S. (2017) Implant placement post extraction in esthetic single tooth sites: When immediate, when early, when late? *Periodontology 2000* **73**, 84-102.

Chu SJ, Sarnachiaro GO, Hochman MN, Tarnow DP. (2015) Subclassification and clinical management of extraction sockets with labial dentoalveolar dehiscence defects. *Compendium of Continuing Education in Dentistry* **36**, 516-522.

Cosyn J, Eghbali A, De Bruyn H, Collys K, Cleymaet R, De Rouck T. (2011) Immediate single-tooth implants in the anterior maxilla: 3-year results of a case series on hard and soft tissue response and aesthetics. *Journal of Clinical Periodontology* **38**, 746-753.

Elian N, Cho S-C, Froum S, Smith RB, Tarnow DP. (2007) A simplified socket classification and repair technique. *Practical Procedures & Aesthetic Dentistry* **19**, 99-104.

Frizzera F, Freitas RM, Muñoz-Chávez OF, Cabral G, Shibli JA, Marcantonio Jr E. (2019) Impact of soft tissue grafts to reduce peri-implant alterations after immediate implant placement and provisionalization in compromised sockets. *International Journal of Periodontics & Restorative Dentistry* **39**, 381-389.

Huynh-Ba G, Pjetursson BE, Sanz M, Cecchinato D, Ferrus J, Lindhe J, Lang NP. (2010) Analysis of the socket bone wall dimensions in the upper maxilla in relation to immediate implant placement. *Clinical Oral Implants Research* **21**, 37-42.

Kan JY, Rungcharassaeng K, Sclar A, Lozada JL. (2007) Effects of the facial osseous defect morphology on gingival dynamics after immediate tooth replacement and guided bone regeneration: 1-year results. *Journal of Oral and Maxillofacial Surgery* **65**, 13-19.

Kan JYK, Rungcharassaeng K, Deflorian M, Weinstein T, Wang HL, Testori T. (2018) Immediate implant placement and provisionalization of maxillary anterior single implants. *Periodontology 2000* **77**, 197-212.

Martins Junior W, Ferraz EP, Beloti MM, Rosa AL, Rosa JCM. (2017) Immediate Dentoalveolar Restoration technique (IDR). Autograft characterization and a case Report. *Journal of Osseointegration* **9**, 305-309.

Montanaro N, Rosa JCM, Pereira LAV, Romanos GE. (2019) Role of the maxillary tuberosity in periodontology and implant dentistry - a review. *Stomatology Edu Journal* **6**, 249-259.

Noelken R, Kunkel M, Wagner W. (2011) Immediate implant placement and provisionalization after long-axis root fracture and complete loss of the facial bony lamella. *International Journal of Periodontics & Restorative Dentistry* **31**, 175-183.

Norero HN, Ibáñez MA. (2018) A new technique for rebuilding the buccal plate during placement of immediate dental implants in an extraction site with buccal defects. *Journal of Implant & Advanced Clinical Dentistry* **10**, 6-15.

Rosa JCM, Rosa DM, Zardo CM, Rosa, ACPO, Canullo L. (2009). Reconstruction of damaged fresh sockets by connective-bone sliver graft from the maxillary tuberosity, to enable immediate dentoalveolar restoration (IDR) - a clinical case. *Implants* **10**, 12-17.

Rosa JCM, Rosa ACPO, Rosa DM, Zardo CM. (2013) Immediate Dentoalveolar Restoration of compromised sockets: A novel technique. *The European Journal of Esthetic Dentistry* **8**, 432-443.

Rosa JCM, Rosa ACPO, Fadanelli MA, Sotto-Maior BS. (2014a) Immediate implant placement, reconstruction of compromised sockets, and repair of gingival recession with a triple graft from the maxillary tuberosity: A variation of the immediate dentoalveolar restoration technique. *The Journal of Prosthetic Dentistry* **112**, 717-722.

Rosa JCM, Rosa ACPO, Francischone CE, Sotto-Maior BS. (2014b) Diameter selection of implants placed in extraction sockets: A new approach. *Dental Press Implantology* **8**, 80-89.

Rosa JCM, Rosa ACPO, Francischone CE, Sotto-Maior BS. (2014c) Esthetic outcomes and tissue stability of implant placement in compromised sockets following immediate dentoalveolar restoration: results of a prospective case series at 58 months follow-up. *The International Journal of Periodontics & Restorative Dentistry* **34**, 199-208.

Rosa JCM, Rosa ACPO, Zardo CM, Rosa DM, Adolfi D, Canullo L. (2014d) *Immediate Dentoalveolar Restoration: Immediate-loaded implants in compromised alveolar sockets.* Chicago: Quintessence Publishing.

Rosa ACPO, Rosa JCM, Pereira LAVD, Francischone CE, Sotto-Maior BS. (2016) Guidelines for selecting the implant diameter during immediate implant placement of a fresh extraction socket: A case series. *The International Journal of Periodontics & Restorative Dentistry* **36**, 401-407.

Rosa JCM, Fadanelli MA, Zimmerman D, Rosa ACPO. (2017) The application of rapid prototyping to improve bone reconstruction in immediate dentoalveolar restoration: A case report. *The International Journal of Esthetic Dentistry* **12**, 258-270.

Rosa JCM, Romanelli J, Calichio LE. (2018) Multidisciplinary approach using slow orthodontic extrusion and the Immediate Dentoalveolar Restoration technique. *Quintessence of Dental Technology* **41**, 189-203.

Rosa JCM, Pereira LAVD. (2019) Predictable esthetic anterior maxillary reconstruction with dental implants and maxillary tuberosity grafts. En: Nevins M, Wang H-L, organizadores. *Implant Therapy: clinical approaches and evidence of success.* 2.ª ed. Chicago: Quintessence Publishing, v. 1, pag. 175-196.

Rosa JCM, Rosa ACPO, Huwais S. (2019) Use of the Immediate Dentoalveolar Restoration Technique combined with osseodensification in periodontally compromised extraction sites. *The International Journal of Periodontics & Restorative Dentistry* **39**, 527-534.

Schneider D, Grunder U, Ender A, Hämmerle CHF, Jung RE. (2011) Volume gain and stability of peri-implant tissue following bone and soft tissue augmentation: 1-year results from a prospective cohort study. *Clinical Oral Implants Research* **22**, 28-37.

Tripodakis AP, Gousias H, Mastoris M, Likouresis D. (2016) Five-year volumetric evaluation of periodontally compromised sites restored by immediate implant restorations. *International Journal of Periodontics & Restorative Dentistry* **36**, 645-653.

Waki T, Kan JYK. (2016) Immediate placement and provisionalization of maxillary anterior single implant with guided bone regeneration, connective tissue graft, and coronally positioned flap procedures. *International Journal of Esthetic Dentistry* **11**, 174-185.