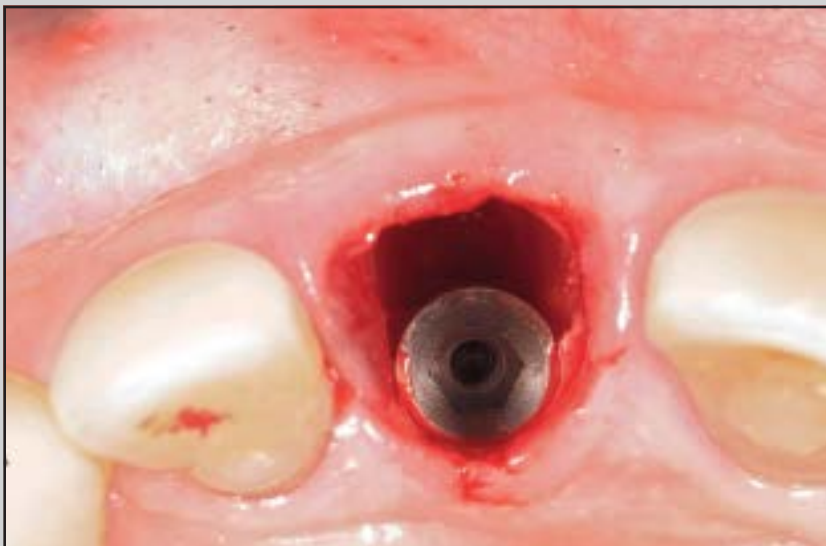
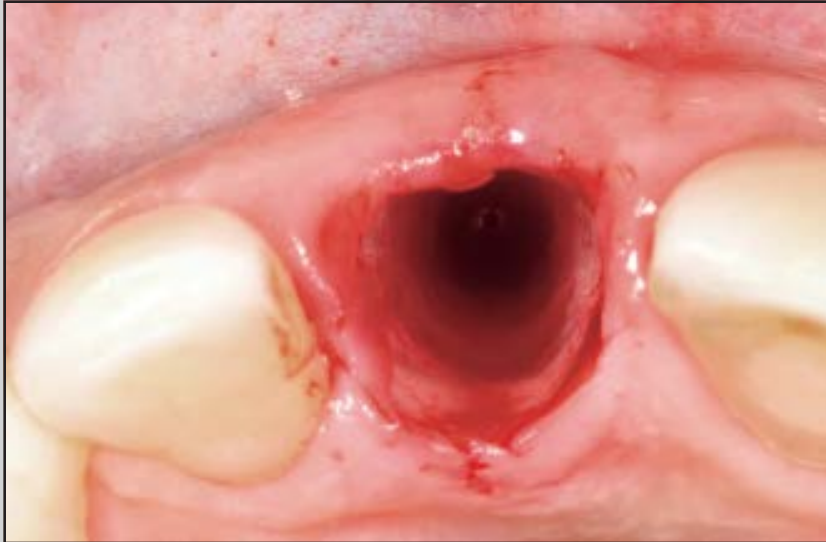
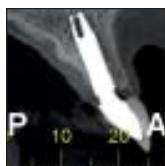Guidelines for Selecting the Implant Diameter During Immediate Implant Placement of a Fresh Extraction Socket: A Case Series



Ariadene Cristina Pértile de Oliveira Rosa, DDS, MSc, PhD¹

José Carlos Martins da Rosa, DDS, MSc, PhD¹

Luís Antônio Violin Dias Pereira, DDS, MSc, PhD²

Carlos Eduardo Francischone, DDS, MSc, PhD³

Bruno Salles Sotto-Maior, DDS, MSc, PhD⁴

This prospective case series proposes a method for selecting the diameter of immediate postextraction anterior implants and guiding the placement position of the implant based on the buccolingual dimension with the goal of preserving the buccal bone wall. The socket buccolingual distance was measured to determine the appropriate implant diameter, considering a 3-mm gap to the buccal wall. Pre- and postoperative cone-beam computed tomography images were compared to evaluate the buccal bone. The socket width measurements were not significantly different ($P = .931$). The mean widths of the postoperative buccal bone were 3.01 ± 0.18 mm, 2.92 ± 0.38 mm, and 2.83 ± 0.42 mm for the crestal bone at the implant platform and at 2 and 4 mm apically, respectively, after 35 months of follow-up. This new diameter selection method for implants demonstrated predictable buccal plate preservation. Int J Periodontics Restorative Dent 2016;36:401–407. doi: 10.11607/prd.2381

According to the 2003 consensus conference of the International Team for Implantology (ITI), immediate implant placement in a fresh extraction socket (type I) has an osseointegration rate similar to that for implants placed in healed sites.^{1,2} However, the technique can result in dimensional changes of the alveolar ridge.³ The height of the ridge can be reduced, and its crest can palatally shift,^{3,4} which might result in esthetic deficiencies. Maintenance of the height and thickness of the buccal bone wall is important for long-term stability of the harmonious gingival margins around the implants.^{5,6}

Reduction of the buccolingual width in the bone ridge occurs 4 to 6 months after the tooth extraction, regardless of the implantation timing.⁷ Although some clinical studies have suggested that implant placement partially counteracts the process of tissue remodeling,^{8,9} other studies provide strong evidence that type I placement (per se) does not prevent ridge resorption in postextraction sites.^{3,10,11} In addition, Covani et al suggested that surgical trauma and the position and diameter of the implant play key roles in buccal bone resorption around implants placed in fresh sockets.¹² The surgical techniques used to minimize bone trauma and the tridimensional position of the implant have

¹PhD in Oral Implantology, Department of Implantology, São Leopoldo Mandic Dental Research Center, Campinas, São Paulo, Brazil.

²Associate Professor, Department of Biochemistry and Tissue Biology, Institute of Biology, State University of Campinas, Campinas, São Paulo, Brazil.

³Full Professor, Department of Implantology, São Leopoldo Mandic Dental Research Center, Campinas, São Paulo, Brazil.

⁴Full Professor, Department of Restorative Dentistry, Federal University of Juiz de Fora, Juiz de Fora, Minas Gerais, Brazil.

Correspondence to: Dr Ariadene Cristina Pértile de Oliveira Rosa,
Av São Leopoldo 680, CEP 95097-350, Caxias do Sul/RS, Brazil.
Email: ariadene@rosaodontologia.com.br

©2016 by Quintessence Publishing Co Inc.

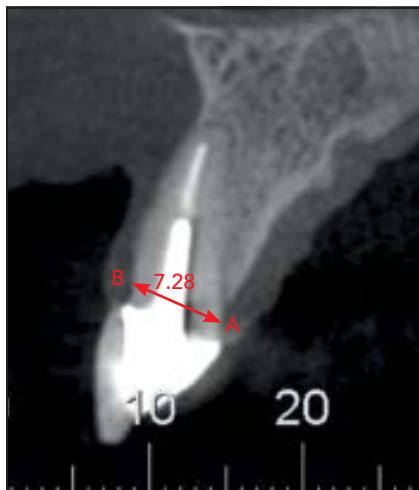


Fig 1 Measurement of the buccolingual distance using cone beam computed tomography to determine the implant diameter.

been extensively studied.⁵ However, discussion of the ideal implant diameter for a fresh extraction socket (type I) has been minimal.

Implants with a regular-neck configuration are most often used in the region of central incisors and canines, and narrow-neck implants are most often placed in lateral incisor sites. Larger diameter implants carry a significant risk of compromising the vascular supply to the buccal plate, which increases the risk of resorption. A common error in immediate implant placement is to position the implant in the center of the socket, when the best position is the palatal anchorage.⁵ In addition, the socket gap should be filled with biomaterial⁴ or a bone graft¹³ to ensure optimal healing of the hard and soft tissues.^{14,15}

Capelli et al suggested that to achieve adequate bone and optimal soft tissue contour when the final distance between the implant surface

to the external surface of the buccal bone plate is < 4 mm, only the peri-implant gap needs to be grafted. When this distance is > 4 mm, external grafting is also necessary.⁴

Considering the importance of implant diameter in preserving the buccal bone wall,^{4,14,15} the present prospective case series was performed to aid in selecting the implant diameter for immediate placement in a fresh extraction socket in the esthetic zone.

Materials and methods

Study design and population

The São Leopoldo Mandic School of Dentistry Ethics Committee and the National Research Ethics Committee (CONEP-MS) approved the research protocol of this prospective case series under protocol number 795.583. This study followed the tenets of the World Medical Association Declaration of Helsinki (2008).

The patient sample included 20 participants who required immediate postextraction implants in maxillary anterior teeth. Moreover, these patients had at least 3 mm of bone apical to the root apex, were older than 18 years of age, were in good general health, and provided informed consent.

The following exclusion criteria were applied: an implant insertion torque of < 30 Ncm; presence of any systemic disease, antitumor chemotherapy, or radiation therapy in the previous 5 years; the absence of an adjacent natural tooth and presence of active periodontal

disease; a smoking history of > 20 cigarettes per day; use of corticosteroids; pregnancy; and inability to return for a follow-up evaluation.

Surgical and prosthetic procedures

Selecting the implant diameter

The buccolingual distance of the socket was measured based on a cone-beam computed tomography (CBCT) cross-sectional image (Fig 1). Using this measurement, the appropriate diameter of the implant was selected to maintain a 3-mm gap between the implant buccal surface and the socket buccal bone wall (see Rosa et al¹⁶). When the buccal bone wall was not present, the gap was considered to exist between the surface of the implant and the internal portion of the buccal soft tissue. Therefore, if the total buccolingual distance of the socket was < 7 mm, the selection of the implant diameter should have a narrow platform (around 3.5 mm). If the distance was 7 mm, the implant diameter should be regular (around 4.3 mm). If the distance was > 7 mm, the implant diameter should have a wide platform (around 5.1 mm). The length of the implant must be 2 or 3 mm longer than the socket length to obtain primary stability.¹⁷

The same surgeon (J.C.M.R.) performed all operations. The teeth were removed with as little trauma as possible. Care was taken to maintain the integrity of the remaining bone walls, gingival margin, and papillae. The socket was then carefully

Fig 2 (left) Clinical confirmation of the buccolingual distance after tooth removal.

Fig 3 (right) The gap between the implant and the buccal socket wall must be 3 mm.

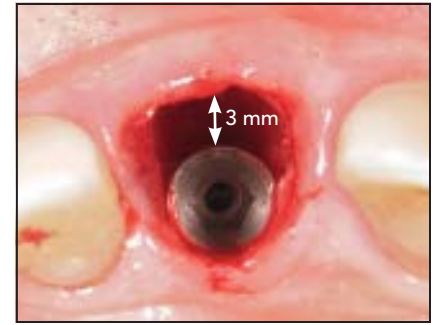
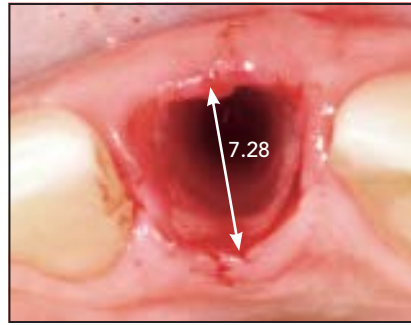
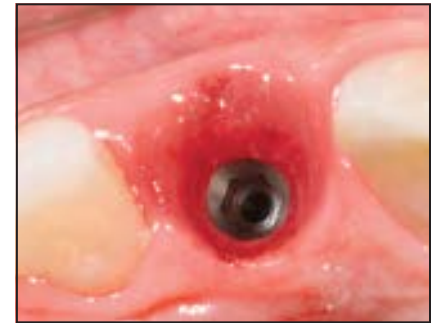
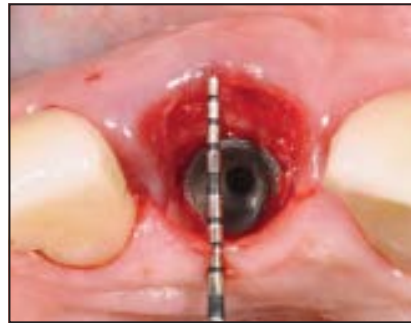
Fig 4 (left) The gap was completely filled with a bone graft harvested from the maxillary tuberosity.

Fig 5 (right) Tissue maturation was observed 4 months after the procedure.



curetted to remove any granulation tissue, and the buccolingual distance was assessed (Fig 2).

Immediate implant placement was performed using 3D positioning of the implant as described by Belser et al, by anchoring the apical third of the implant into the upper bone socket.¹⁸ The implant shoulder was placed in the palatal bone wall using a surgical guide, allowing the 3-mm gap to the buccal wall to be obtained (Fig 3). The primary stability should range from 30 Ncm to 65 Ncm.

After implant insertion, the gap was grafted using particulate autogenous cancellous bone harvested from the maxillary tuberosity (Fig 4). In patients with buccal bone wall defects, the missing socket wall was

reconstructed using a corticocancellous graft harvested from the same donor site, following the immediate dentoalveolar restoration technique.¹³ The particulate bone was then compacted until it completely filled the gaps between the corticocancellous graft and the implant surface.¹³

Postoperatively, prosthetic abutments were connected over the implants and resin provisional crowns were placed to seal the gingival margin.⁶ No sutures were placed at the receptor site. The ideal emergence profile with a concave contour was established on the provisional prosthesis, allowing free space to accommodate the soft tissue for observations 4 months after the procedure (Fig 5).

CBCT evaluation

All CBCT scans were acquired by soft tissue CBCT technique using the i-CAT 3D Imaging System (Imaging Sciences International).¹⁹ The maxillae were scanned preoperatively as well as postoperatively at the follow-up. The mean follow-up time was 35.45 months. Sagittal sections measuring 1 mm thick were obtained as CBCT reconstructions.

A previously trained examiner (A.C.P.O.R.) independently assessed all CBCT sagittal section images. For the measurements, the most central sagittal section of each tooth (preoperative CBCT) and each implant (postoperative CBCT) were selected. Using Image Tool software, the examiner made four distinct socket

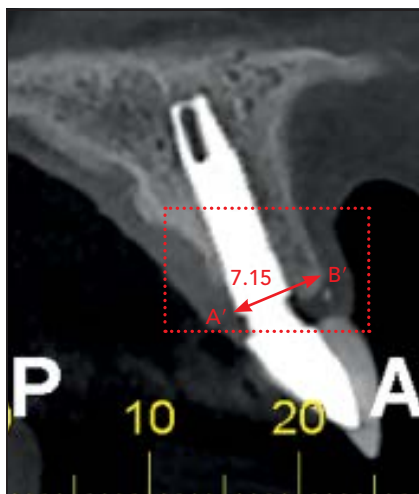



Fig 6 (left) Measurement of the post-operative buccolingual distance using cone beam computed tomography.

Fig 7 (below) Lines C, D, and E indicate the buccal bone plate measurements taken at the platform level and 2 and 4 mm apical to the implant, respectively.



measurements. Two landmarks were defined: the lingual gingival margin (A) and the buccal gingival margin (B). Measurement A–B indicated the preoperative socket size (Fig 1). Measurement A–B' indicated the postoperative socket size (Fig 6). Measurement C was the perpendicular line from the outer border of the bone crest to the implant platform. Measurements D and E were parallel apical lines from between 2 and 4 mm, respectively, from the outer border of the bone crest to the implant. Measurements C, D, and E indicate buccal bone plate preservation (Fig 7).

The measurements were performed at three time points in 2-week intervals (at minimum), and the mean and standard deviation (SD) were calculated for each reference measurement. The examiner recording the second set of measurements was blinded to the first set to evaluate the reliability of the recordings.

Data and statistical analyses

SPSS 17.0 (IBM) was used for all calculations. The level of significance was set at 5%. The intraobserver reproducibility of the measurements was calculated using kappa statistics based on the difference between the duplicate recordings made by the same examiner. The means, SDs, and confidence intervals (CIs) were calculated for each measurement. The data were examined using the Kolmogorov-Smirnov test, which demonstrated that the data were normally distributed. The mean socket sizes were compared at baseline and follow-up using the *t* test for paired values. The alpha error was set at .05.

Results

Surgical and prosthetic complications were not observed during the evaluation period (35.00 ± 10.59

months). Of the implants placed, 5 were narrow platform (3.5 mm), 13 were regular platform (4.3 mm), and 2 were wide platform (5.1 mm), according to the socket diameter. The lengths ranged from 11.5 to 16.0 mm, according to the available apical bone (1 implant with 11.5 mm, 9 implants with 13 mm, 8 implants with 15 mm, and 2 implants with 16 mm). Of the 20 implants placed, 17 were located in the maxillary central incisor region (85%), 2 were lateral incisors (10%), and 1 was located in the canine region (5%) (Table 1, Fig 8).

None of the intraexaminer measurements significantly differed ($P > .05$, kappa = 0.79). During the preoperative period, the mean width of the extraction socket entrance was 7.07 ± 0.37 mm. After a follow-up healing period, the mean implanted socket entrance width was 7.09 ± 0.35 mm. The difference was not significant ($P = .931$). The mean buccal bone plate measurements were 3.01 ± 0.18 mm, 2.92 ± 0.38 mm, and 2.83 ± 0.42 mm in the crestal bone at the implant platform and 2 and 4 mm apically, respectively (Table 1).

Discussion

Implant placement in fresh extraction sockets is a highly predictable procedure.^{20,21} However, a risk of resorption remains for the buccal bone plate and esthetic impairments have been observed in long-term follow-ups.⁷ The current case series used a specific protocol to select the implant diameter for com-

Table 1 Clinical information and outcomes

Patient	Tooth (FDI)	Implant size (mm)	Follow-up time (mo)	Measurement (mm)				
				A-B	A-B'	C	D	E
1	11	16 × 4.3	31	6.98	7.01	3.01	3.02	2.99
2	11	15 × 5.1	49	8.05	7.95	2.93	2.87	2.80
3	21	13 × 4.3	44	7.12	7.05	2.89	2.91	2.81
4	21	13 × 4.3	42	7.01	7.03	3.25	3.21	3.15
5	21	15 × 3.5	53	6.55	6.50	3.15	3.05	2.90
6	11	13 × 3.5	23	6.73	6.80	3.20	3.15	2.89
7	12	15 × 4.3	43	7.21	7.43	2.99	2.98	2.93
8	11	11.5 × 4.3	45	6.93	6.80	3.59	3.62	3.50
9	13	13 × 5.1	51	7.68	7.77	3.44	3.40	3.23
10	23	13 × 4.3	24	7.03	7.10	3.01	3.04	2.99
11	11	15 × 4.3	16	7.05	7.05	3.10	3.10	3.10
12	11	13 × 4.3	37	7.21	7.15	3.05	3.04	2.99
13	21	15 × 3.5	22	6.63	6.77	3.15	3.05	3.00
14	11	13 × 4.3	32	7.28	7.15	2.90	2.89	2.77
15	11	13 × 4.3	36	7.33	7.40	3.03	3.05	3.01
16	21	16 × 3.5	30	6.47	6.55	2.75	2.71	2.56
17	11	15 × 4.3	36	7.11	7.15	3.01	3.04	3.07
18	11	15 × 4.3	38	6.99	7.02	2.89	2.77	2.68
19	21	13 × 4.3	18	7.44	7.39	2.89	2.77	2.70
20	11	15 × 3.5	30	6.65	6.89	3.03	3.06	3.01
Mean	–	–	35.00 ± 10.59	7.07 ± 0.37	7.09 ± 0.35	3.06 ± 0.19	3.03 ± 0.30	2.95 ± 0.20

A-B = preoperative socket size; A-B' = postoperative socket size; C = the perpendicular line from the outer border of the bone crest to the implant platform; D = the perpendicular line from 2 mm apical to the outer border of the bone crest to the implant; E = the perpendicular line from 4 mm apical to the outer border of the bone crest to the implant platform. Measurements C, D, and E indicate buccal bone plate preservation.

promised or intact fresh extraction sockets,¹⁶ which resulted in minimal hard tissue alterations following tooth extraction as well as immediate implant placement, autogenous bone graft, and provisional crown installation.

The authors propose using the buccal-lingual distance to select the diameter of the immediate implant for the postextraction socket, maintaining at least 3 mm between the surface of the implant and the buccal bone wall to ensure the dimensional stability of peri-implant

tissues. When the buccal bone wall is not present, the gap is considered to exist between the surface of the implant and the internal portion of the buccal soft tissue. In such cases, regenerative techniques such as immediate dentoalveolar restoration¹³ or guided bone regeneration²² must be performed following implant placement.

Maintaining the buccal plate is clinically relevant to avoid midfacial recession, an important esthetic parameter.^{20,23} To attain long-term stability of the soft tissue, in the present

case series the gap between the surface of the implant and the buccal bone wall was filled with an autogenous bone graft harvested from the maxillary tuberosity,¹³ and the result demonstrated no differences in the socket dimensions. In addition, this study used three horizontal measurements to evaluate the predictability of all buccal bone maintenance.⁴

In previous clinical studies, the maxillary anterior tooth revealed that approximately 90% of the buccal plates were ≤ 1 mm thick.^{24,25} This

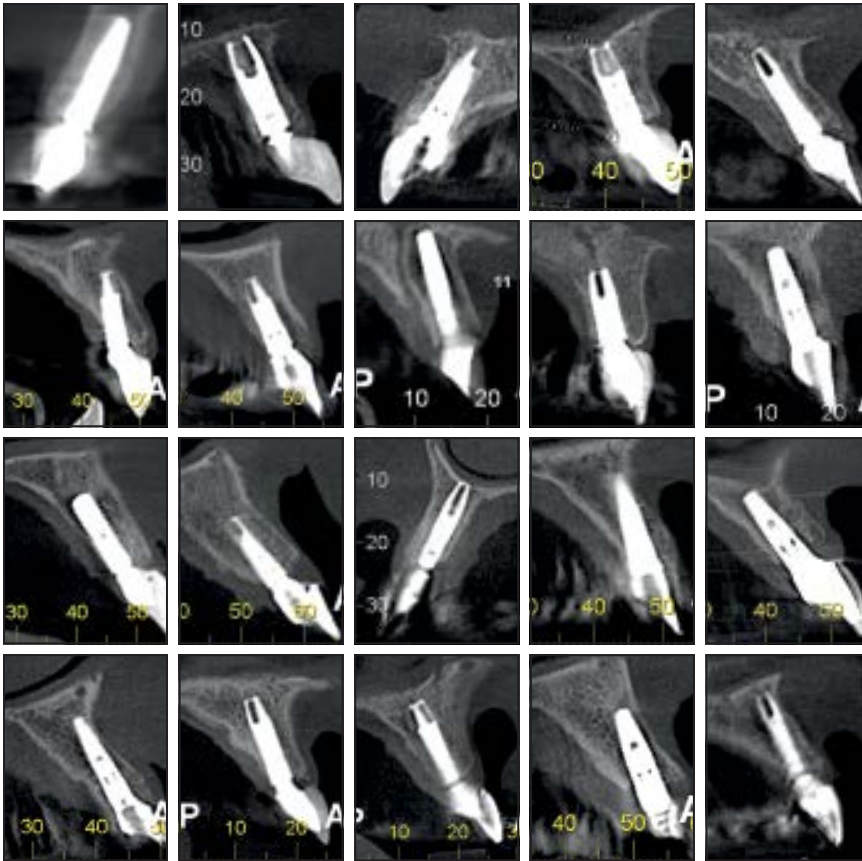


Fig 8 All postoperative cone beam computed tomography images.

1-mm thickness might be primarily composed of cortical bone. The dental buccal bone plate has three blood supply sources: the periodontal ligament, buccal periosteum, and endosseous marrow.⁷ The ligament blood supply is absent around the implant and might impair buccal bone plate maintenance. Increasing the thickness of the buccal bone using an autogenous graft in contact with the implant might facilitate blood supply to the buccal wall. However, when a large-diameter implant is placed, the blood supply is compromised due to the absence of the periodontal ligament and in-

sufficient endosseous marrow to provide adequate vascularization, especially on the top of the buccal bone.

Previous investigators have suggested that at least 2 mm of presurgical buccal bone is needed for optimal healing of hard and soft tissues when placing implants in fresh extraction sites.^{4,14,15} The present study shows that selecting the implant diameter to maintain a 3-mm gap between the buccal surface of the implant and the buccal bone wall offers predictable results in maintaining the stability and vascularization of the buccal plate.

In addition, the present study used maxillary tuberosity autogenous bone graft to fill the socket gap. Numerous vital periosteal and endosteal bone lining cells are present in the tuberosity.²⁶ The revascularization pattern is vital for bone-grafting success, and the trabecular structure of the bone graft harvested from the tuberosity facilitates high revascularization and release of bone growth factors to the receptor site.²⁷ This donor site is disadvantageous due to the limited amount of bone available for grafting; nevertheless, the volume harvested was enough for reconstruction or to fill the socket gaps after immediate implant placement.¹³

The lack of a control group is the primary limitation of all observational studies, including this case series. However, the preliminary study showed favorable maintenance of peri-implant tissues. This might be useful in designing future studies, including randomized controlled trials.²⁶ Another limitation of this study was the presence of metallic artifacts at the measurement sites that could decrease image quality. However, what differentiates the present study from previous studies is that the CBCT images were obtained through soft tissue CBCT technique,¹⁹ which increased the accuracy of the measurements.²⁷

Conclusions

The proposed method for selecting the diameter of single immediate anterior implants in fresh extraction sockets showed favorable results

in buccal plate preservation after a mean follow-up period of 34.45 months.

Acknowledgments

The authors reported no conflicts of interest related to this study.

References

- Cooper LF, Reside GJ, Raes F, et al. Immediate provisionalization of dental implants placed in healed alveolar ridges and extraction sockets: A 5-year prospective evaluation. *Int J Oral Maxillofac Implants* 2014;29:709–717.
- De Bruyn H, Raes F, Cooper LF, et al. Three-years clinical outcome of immediate provisionalization of single Osseospeed implants in extraction sockets and healed ridges. *Clin Oral Implants Res* 2013;24:217–223.
- Araújo MG, Wennström JL, Lindhe J. Modeling of the buccal and lingual bone walls of fresh extraction sites following implant installation. *Clin Oral Implants Res* 2006;17:606–614.
- Capelli M, Testori T, Galli F, et al. Implant-buccal plate distance as diagnostic parameter: A prospective cohort study on implant placement in fresh extraction sockets. *J Periodontol* 2013;84:1768–1774.
- Buser D, Martin W, Belser UC. Optimizing esthetics for implant restorations in the anterior maxilla: Anatomic and surgical considerations. *Int J Oral Maxillofac Implants* 2004;19(suppl):43–61.
- Rosa JC. Immediate Dentoalveolar Restoration: Immediately Loaded Implants in Compromised Sockets. Chicago: Quintessence, 2014.
- Tarnow DP, Chu SJ, Salama MA, et al. Flapless postextraction socket implant placement in the esthetic zone: Part 1. The effect of bone grafting and/or provisional restoration on facial-palatal ridge dimensional change—a retrospective cohort study. *Int J Periodontics Restorative Dent* 2014;34:323–331.
- Paolantonio M, Dolci M, Scarano A, et al. Immediate implantation in fresh extraction sockets. A controlled clinical and histological study in man. *J Periodontol* 2001;72:1560–1571.
- Watzek G, Haider R, Mensdorff-Pouilly N, Haas R. Immediate and delayed implantation for complete restoration of the jaw following extraction of all residual teeth: A retrospective study comparing different types of serial immediate implantation. *Int J Oral Maxillofac Implants* 1995;10:561–567.
- Araújo MG, Linder E, Lindhe J. Bio-Oss collagen in the buccal gap at immediate implants: A 6-month study in the dog. *Clin Oral Implants Res* 2011;22:1–8.
- Chen ST, Buser D. Clinical and esthetic outcomes of implants placed in postextraction sites. *Int J Oral Maxillofac Implants* 2009;24(suppl):186–217.
- Covani U, Cornelini R, Calvo JL, Tonelli P, Barone A. Bone remodeling around implants placed in fresh extraction sockets. *Int J Periodontics Restorative Dent* 2010;30:601–607.
- Rosa JC, Rosa AC, Francischone CE, Sotto-Maior BS. Esthetic outcomes and tissue stability of implant placement in compromised sockets following immediate dentoalveolar restoration: Results of a prospective case series at 58 months follow-up. *Int J Periodontics Restorative Dent* 2014;34:199–208.
- Grunder U. Crestal ridge width changes when placing implants at the time of tooth extraction with and without soft tissue augmentation after a healing period of 6 months: Report of 24 consecutive cases. *Int J Periodontics Restorative Dent* 2011;31:9–17.
- Qahash M, Susin C, Polimeni G, Hall J, Wikesjö UM. Bone healing dynamics at buccal peri-implant sites. *Clin Oral Implants Res* 2008;19:166–172.
- Rosa JC, Rosa AC, Francischone CE, Sotto-Maior BS. Diameter selection of implants placed in extraction sockets: A new approach. *Dental Press Implantology* 2014;8:80–89.
- Chrcanovic BR, Albrektsson T, Wennerberg A. Dental implants inserted in fresh extraction sockets versus healed sites: A systematic review and meta-analysis. *J Dent* 2015;43:16–41.
- Belser U, Buser D, Higginbottom F. Consensus statements and recommended clinical procedures regarding esthetics in implant dentistry. *Int J Oral Maxillofac Implants* 2004;19(suppl):73–74.
- Janúario AL, Barriviera M, Duarte WR. Soft tissue cone-beam computed tomography: A novel method for the measurement of gingival tissue and the dimensions of the dentogingival unit. *J Esthet Restor Dent* 2008;20:366–373.
- Alharbi HM, Babay N, Alzoman H, Basudan S, Anil S, Jansen JA. Bone morphology changes around two types of bone-level implants installed in fresh extraction sockets—A histomorphometric study in Beagle dogs. *Clin Oral Implants Res* 2015;26:1106–1112.
- Barone A, Toti P, Piattelli A, et al. Extraction socket healing in humans after ridge preservation techniques: Comparison between flapless and flapped procedures in a randomized clinical trial. *J Periodontol* 2014;85:14–23.
- Kaminaka A, Nakano T, Ono S, Kato T, Yatani H. Cone-beam computed tomography evaluation of horizontal and vertical dimensional changes in buccal peri-implant alveolar bone and soft tissue: A 1-year prospective clinical study. *Clin Implant Dent Relat Res* 2015;17(suppl 2):e576–e585.
- Araújo MG, da Silva JC, de Mendonça AF, Lindhe J. Ridge alterations following grafting of fresh extraction sockets in man. A randomized clinical trial. *Clin Oral Implants Res* 2015;26:407–412.
- Ferrus J, Cecchinato D, Pjetursson EB, Lang NP, Sanz M, Lindhe J. Factors influencing ridge alterations following immediate implant placement into extraction sockets. *Clin Oral Implants Res* 2010;21:22–29.
- Huynh-Ba G, Pjetursson BE, Sanz M, et al. Analysis of the socket bone wall dimensions in the upper maxilla in relation to immediate implant placement. *Clin Oral Implants Res* 2010;21:37–42.
- Kooistra B, Dijkman B, Einhorn TA, Bhandari M. How to design a good case series. *J Bone Joint Surg Am* 2009;91(suppl 3):21–26.
- Wood R, Sun Z, Chaudhry J, et al. Factors affecting the accuracy of buccal alveolar bone height measurements from cone-beam computed tomography images. *Am J Orthod Dentofacial Orthop* 2013;143:353–363.