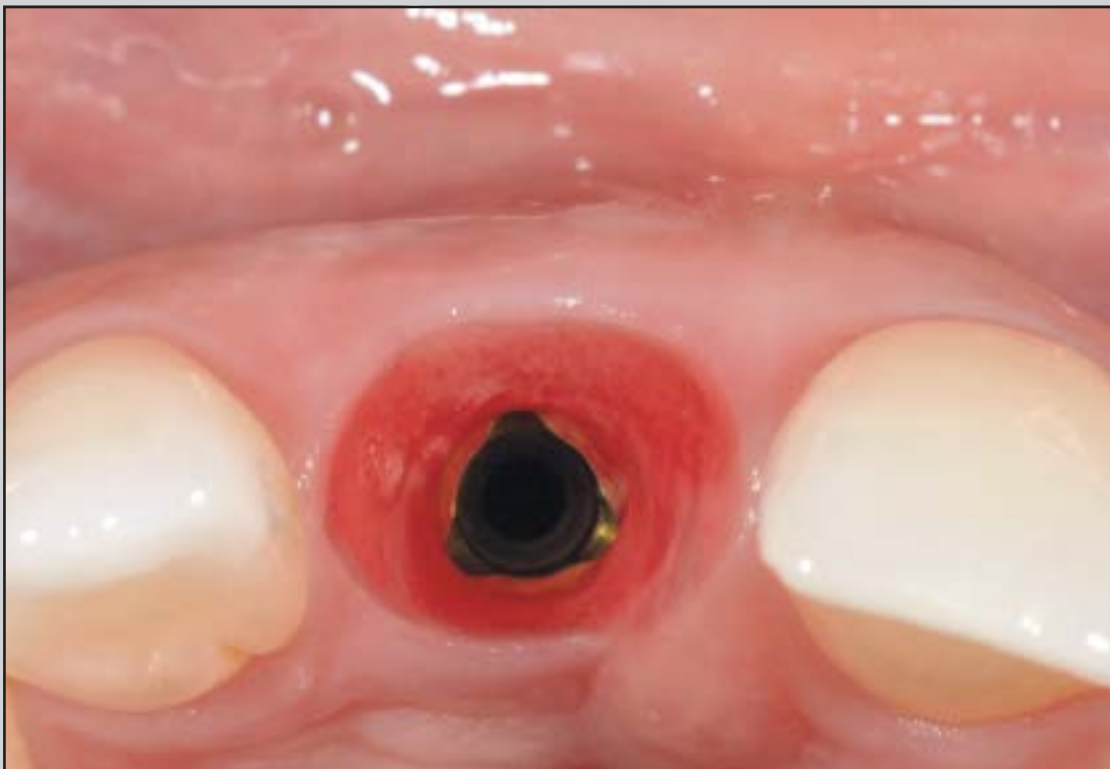
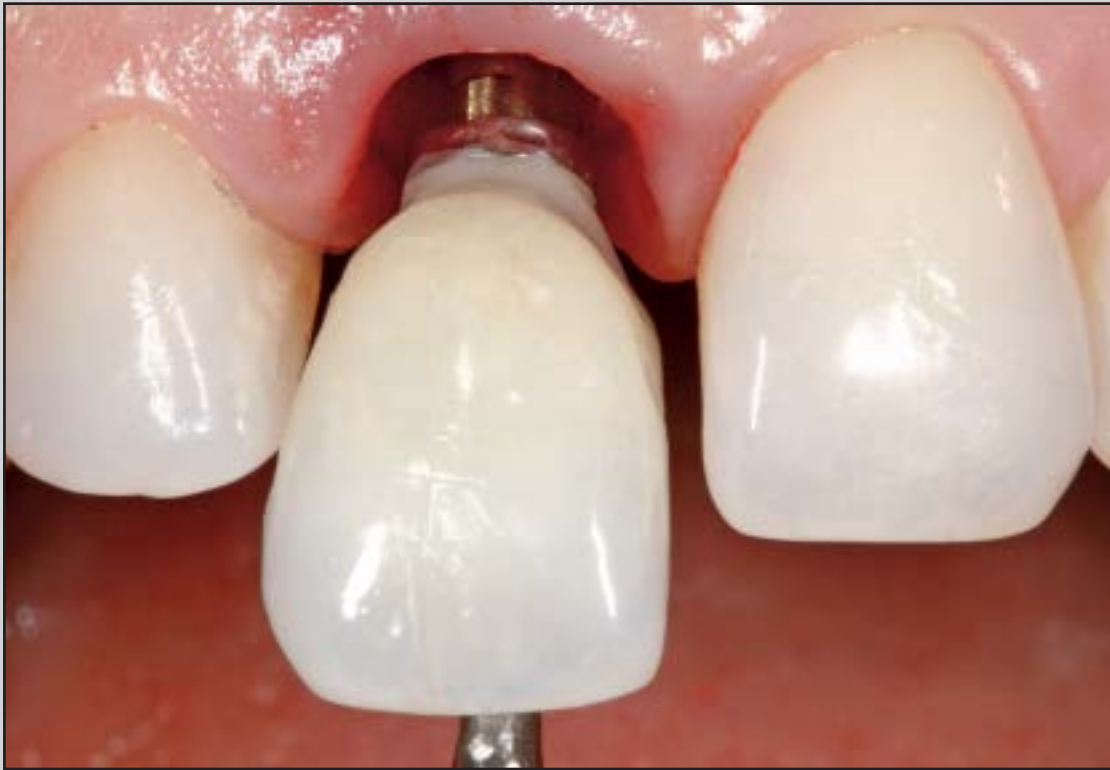
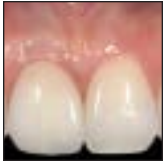Esthetic Outcomes and Tissue Stability of Implant Placement in Compromised Sockets Following Immediate Dentoalveolar Restoration: Results of a Prospective Case Series at 58 Months Follow-up



José Carlos Martins da Rosa, DDS, MSc¹
 Ariádene Cristina Pértile de Oliveira Rosa, DDS, MSc¹
 Carlos Eduardo Francischone, DDS, MSc, PhD²
 Bruno Salles Sotto-Maior, DDS, MSc, PhD³

The aim of this prospective case series was to evaluate the stability of esthetic treatment after single tooth replacement in compromised sockets using the immediate dentoalveolar restoration (IDR) concept. Eighteen patients underwent immediate implant placement and IDR of bone defects. Clinical photographs were used to evaluate the gingival contour and papillae. The mean soft tissue dimensions at baseline and final follow-up were 12.85 ± 2.33 mm and 12.79 ± 2.48 mm, respectively, revealing no recession. The mean mesial and distal papillary heights increased slightly over time. Stable peri-implant soft tissues and satisfactory esthetic outcomes were achieved. (Int J Periodontics Restorative Dent 2014;34:199–208. doi: 10.11607/prd.1858)

¹PhD Student, Department of Implantology, São Leopoldo Mandic Dental Research Center, Campinas, São Paulo, Brazil.

²Full Professor, Department of Implantology, São Leopoldo Mandic Dental Research Center, Campinas, São Paulo, Brazil.

³Full Professor, Department of Restorative Dentistry, Federal University of Juiz de Fora, Juiz de Fora, Minas Gerais, Brazil.

Correspondence to: Dr José Carlos Martins da Rosa, Av. São Leopoldo 680, CEP 95097-350, Caxias do Sul, RS, Brazil; email: josecarlos@rosaodontologia.com.br.

©2014 by Quintessence Publishing Co Inc.

Implant placement after extraction of a single tooth is a commonly encountered clinical treatment. However, it is a challenge for clinicians and is rated as either advanced or complex in terms of its difficulty level.^{1–3} Currently, the goal of esthetic dentistry is to achieve the most inconspicuous reconstruction or replacement of missing teeth and peri-implant hard and soft tissue components.^{4,5} Nevertheless, the reasons for tooth extraction and immediate implant placement, such as endodontic failure, advanced periodontal disease, trauma, and root fracture, are frequently associated with severe alveolar bone resorption and soft tissue loss.^{6,7} The lack of a facial bone wall to support the facial mucosa and/or the three-dimensional (3D) malpositioning of the implant can cause recession and incomplete papillae.⁸ Thus, implant treatment goals must be expanded to include the reconstruction of these lost structures.

Surgical reconstruction of 3D bone deficiencies in esthetic areas has relied largely on mandibular bone block grafts^{8,9} that are used alone or in combination with a

barrier membrane to minimize graft resorption during healing or on guided bone regeneration (GBR).² Resorption may limit the positive impact of grafting on the esthetic outcome. Ridge reconstruction surgery has been associated with an impaired esthetic outcome.^{10,11} Cosyn and coauthors⁸ demonstrated that esthetic complications after such surgeries are mainly related to incomplete distal papillae. However, some clinical studies^{1,2,12} have shown predictable esthetic results with bone block grafts and GBR.

To improve the clinical efficacy and esthetic success of the surgical reconstructive procedure and immediate implant placement, the stability of the surrounding soft tissues must be evaluated after a medium-term follow-up period. Therefore, the aim of this prospective study was to evaluate the stability of esthetic treatment outcomes after single tooth replacement in compromised fresh sockets using the immediate dentoalveolar restoration (IDR) technique.

Method and materials

Patients and study design

This prospective case series study involved a mean 58.56 ± 8.19 months of follow-up. The study was conducted in accordance with the Helsinki Declaration and was reported according to STROBE (Strengthening the Reporting of Observational Studies in Epidemiology) guidelines. All included patients provided written informed

consent before participating in this study.

Of 24 patients who were undergoing treatment at a private dental office, 18 were selected and agreed to participate in this study. The patients were screened according to the following inclusion criteria: the need for single tooth replacement in the esthetic zone (premolars, canines, and lateral or central incisors) of the maxilla with class Ib or Ic¹³ deficiencies of the facial bone wall due to trauma, radicular fracture or resorption, endodontic or periodontal treatment failure, caries destruction, or a prosthetically nonrepairable crown; the absence of bruxism and parafunctions; and good oral hygiene and compliance. Exclusion criteria were as follows: insertion torque lower than 35 Ncm, general contraindications to implant surgery, uncontrolled diabetes mellitus, history of radiation therapy in the head or neck region, past or current treatment with bisphosphonate therapy, and pregnancy. The soft tissue biotype was not regarded as an exclusion criterion.

Cone beam computed tomography, study plaster casts, and standard clinical photographs were used for rehabilitation planning. The gingival biotype of each patient was assessed preoperatively. The gingival biotype was categorized as thin if a periodontal probe placed into the labial gingival sulcus of the maxillary anterior teeth could be observed through the examined gingiva and as thick if no evidence of the underlying probe was observed.¹⁴

Treatment

All patients received 1 g of amoxicillin (or, if allergic, 1 g of azithromycin) and 8 mg of dexamethasone 1 hour before surgery. Patients were instructed to wash their mouths with 0.12% chlorhexidine solution for 30 seconds immediately prior to surgery. The same surgeon (JCMR) performed all surgeries using the protocol for IDR published by Rosa et al.^{15,16} Local anesthesia consisting of 2% mepivacaine with norepinephrine was administered. Next, the teeth scheduled for immediate replacement were removed as atraumatically as possible using periotomes and minilevers after a minimal incision had been made around the tooth with a microblade (69 WS, Swann-Morton). Care was taken to maintain the integrity of the remaining bone wall and papillae during removal. Afterwards, the socket was checked and carefully curetted to remove any granulation tissue.

Immediate implant placement (NobelReplace Tapered TiUnite, Nobel Biocare) was performed through 3D positioning of the implant as described by Buser et al¹⁷ by anchoring the apical third of the implant into the bone upper socket. All implants were placed in the cingulum axis of the extracted tooth to anchor them in the palatal bone wall. The implant diameter and length depended on the dimensions of the extraction site. Measurements from the most apical bone level to the implant platform and the mesiodistal socket bone defect were assessed to determine

the anatomical shape of the defect. After primary stability had been confirmed (> 35 Ncm), a provisional crown was applied using veneers that were previously prepared with light-curing composite resin. The ideal emergence profile, with a concave contour, was established on the provisional prosthesis, allowing free space to accommodate the soft tissue, thereby promoting a thicker and more stable margin of gingival tissue after the healing period. The provisional restoration was then removed for finishing and polishing and to reconstruct bone defects in the socket.

Local anesthesia with 2% mepivacaine with norepinephrine was administered in the donor area (maxillary tuberosity). A crestal incision was made at the center of the edge of the maxillary tuberosity up to the distal face of the last molar. The incision was deepened along the entire length of the incision until the bony tissue was scratched. In some cases, there was no need for a relaxing incision because the available access area was sufficiently large. Prior mapping of the defect in the receptor area enabled precise technique and access to the donor area. An appropriate chisel, which depended on the bone defect shape, was selected to harvest the graft. Specifically, the width of the chisel was chosen to be 2 mm greater than the width of the bony defect to be reconstructed.

After harvesting the bone graft from the tuberosity, it was prepared by following a very rigorous evaluation of the compromised alveolar walls of the recipient site.

A rongeur was used to conform the edges of the graft, copying the morphology of the previously mapped defect. This step was performed meticulously while testing the corticocancellous graft in the receptor bed until proper adaptation was achieved.

The graft was carefully inserted into the defect between the implant and the mucosa. It was positioned so that it remained juxtaposed to the remaining bone walls, reconstructing the socket, with the cortex turned toward the vestibule. A biologic distance of 2 to 3 mm below the gingival margin was respected. Subsequently, particulate cancellous bone was inserted and packed to fill the spaces between the previously positioned corticocancellous bone graft and the implant surface. The provisional crown was placed onto the implant, and the donor region was sutured with simple sutures.

Postoperatively, all patients received 500 mg of amoxicillin three times a day (or, if allergic, 500 mg of azithromycin, twice a day) for 10 days and 4 mg of dexamethasone twice a day for 3 days. Patients were advised to rinse their mouths carefully with chlorhexidine solution twice a day for 14 days. The definitive cemented restoration with a metal-ceramic or zirconia-ceramic restoration and customized abutment with subgingival contours were accomplished approximately 6 months after surgery. The cement line was established between 0.5 and 1 mm below the gingival margin. A single experienced prosthodontist (JCMR) performed all prosthetic procedures.

Outcome variables

Follow-up visits were scheduled for 2 weeks and 1, 3, and 12 months during the first year postoperatively, and annually thereafter. The implant success rate was defined as the absence of mobility or painful symptoms, absence of radiolucency during radiographic evaluation, and progressive marginal bone loss (MBL) of less than 1 mm during the first year of implant placement and less than 0.2 mm per year in subsequent years. Clinical mobility due to implant overloading, implant fracture, or unsuccessfully treated peri-implantitis necessitated implant removal.

One previously calibrated researcher (ACPOR) performed all esthetic evaluations related to the soft tissue and implant crowns. This researcher was not involved in any of the treatment steps. Soft tissue esthetics and crown parameter states were evaluated using the gingivomorphometry method according to Weinländer et al.¹⁸ Two clinically standardized oral photographs were obtained 1 week after definitive crown delivery and at the last follow-up visit (4 to 6 years postsurgery). These photographs included at least one adjacent tooth on each side and were performed under the same lighting conditions and with similar framing.

The acquired data files were saved as JPEG files and imported into an image-processing software program (Image Tool). With the help of this software, two reference lines (L1 and L2) were created, connecting the gingival zenith to

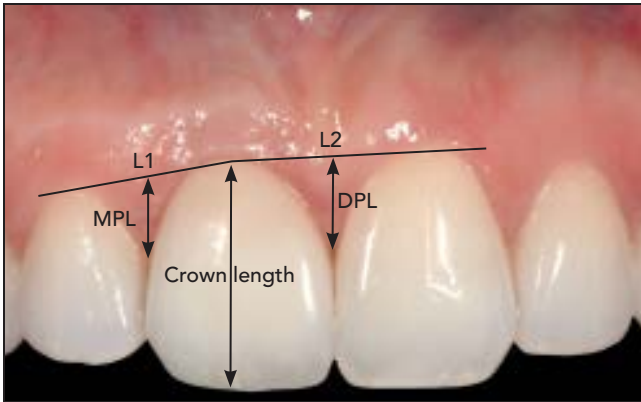


Fig 1 Three different esthetic parameters evaluated (patient 1).

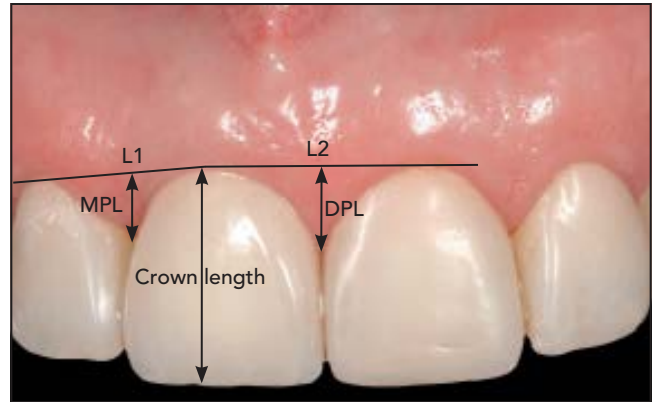


Fig 2 Three different esthetic parameters evaluated (patient 2).

the evaluated and adjacent teeth (Figs 1 and 2). These lines served as standard orientation markers for the intended gingivomorphometric measurements. The following three soft tissue parameters were measured around the crowns: the mesial and distal papillary heights (MPL and DPL, respectively) and crown height (recession). The average of three measurements was calculated for each parameter.

Statistical analyses

The collected data were analyzed with the SPSS software package (version 17.0, IBM). Data were reported as the means \pm SDs for all clinical and esthetic parameters. Differences in the crown height and the mesial and distal papillary dimensions before and after surgery were compared with the paired *t* test.

Results

Twenty-four patients agreed to participate and were consecutively enrolled in the study. Two patients were excluded during the course of the study because they refused to attend their scheduled follow-up appointments. An additional four patients were excluded due to prosthetic treatment of the adjacent tooth. Thus, 18 patients (10 men, 8 women) were treated with implants in the maxillary esthetic region due to extraction of natural teeth (11 central incisors, 3 lateral incisors, 4 premolars; Table 1). Figures 3 to 14 show the sequence of the IDR technique of two patients from this study.

The thin and thick gingival biotypes were identified in 11 (61.12%) and 7 patients (38.88%), respectively. All implants were still functioning after a mean follow-up of 58.56 ± 8.19 months, yield-

ing implant success and prosthesis survival rates of 100%. The mean implant length and diameter were 13.2 and 3.85 mm, respectively. The mean insertion torque was 42.6 ± 7.9 Ncm.

Changes in the peri-implant soft tissue dimensions during the follow-up period are reported in Table 2. The mean dimensions at baseline and at the final follow-up (after a mean 58.56 months) were 12.85 ± 2.33 mm and 12.79 ± 2.48 mm, respectively ($P = .546$). This finding indicates that no recession occurred during the evaluated period. In contrast, the mean MPL and DPL values increased slightly over time ($P = .045$ and $P = .041$, respectively), indicating an increase in papillary height around the definitive restorations (Table 2).

Table 1 Patient characteristics

Patient no.	Sex	Follow-up (mo)	Age (y)	Diameter/length of implant (mm)	Bone defect	Reason for extraction	Gingival biotype
1	Female	73	54	5.0/16	lb	Root fracture	Thick
2	Female	70	38	3.5/16	lc	Root fracture	Thin
3	Female	70	53	4.3/13	lc	Periapical lesion	Thin
4	Female	68	70	4.3/16	lc	Root fracture	Thin
5	Female	64	47	4.3/13	lb	Caries/periapical lesion	Thin
6	Female	64	47	5.0/13	lc	Root fracture	Thin
7	Male	64	49	5.0/13	lc	Caries/periapical lesion	Thin
8	Male	63	47	5.0/16	lc	Caries/periapical lesion	Thick
9	Female	57	39	4.3/16	lb	Root fracture	Thick
10	Male	58	60	4.3/13	lc	Root resorption	Thin
11	Male	55	66	4.3/13	lc	Root fracture	Thick
12	Male	55	52	4.3/13	lb	Periapical lesion/ periodontal disease	Thin
13	Male	52	40	5.0/16	lb	Periodontal disease	Thick
14	Male	52	77	4.3/16	lb	Root fracture	Thick
15	Male	51	78	5.0/13	lc	Root fracture	Thin
16	Male	51	24	4.3/13	lc	Periapical lesion/ Periodontal disease	Thin
17	Female	68	51	4.3/13	lc	Periodontal disease	Thick
18	Male	64	56	4.3/13	lc	Root fracture	Thin

Fig 3 (a) Initial clinical evaluation. The right central incisor was avulsed during an accident. After several attempts at endodontic treatment and apicectomies, the patient remained in pain and the tooth was indicated for extraction. (b) Tooth removed using minimally invasive dental extraction (patient 1).

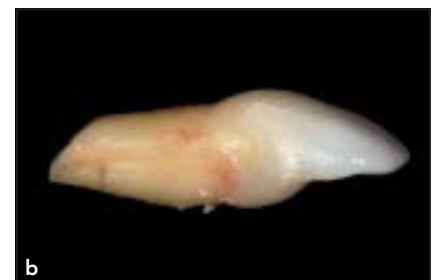
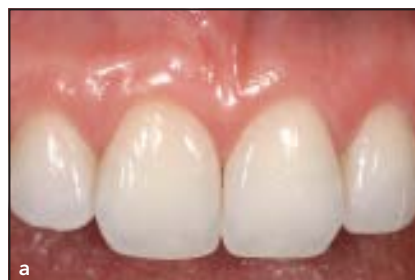
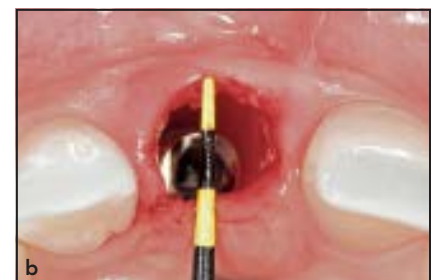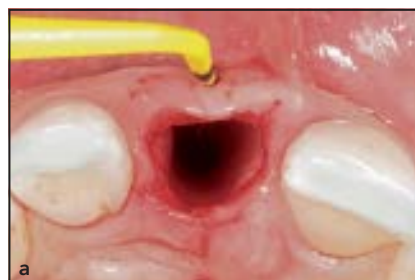Fig 4 (a) After dental extraction, the buccal bone loss was confirmed clinically, and the bone defect shape was measured before and (b) after implant placement. The implant was anchored in the palatal wall, providing a bone defect of approximately 3 mm in thickness to be reconstructed (patient 1).



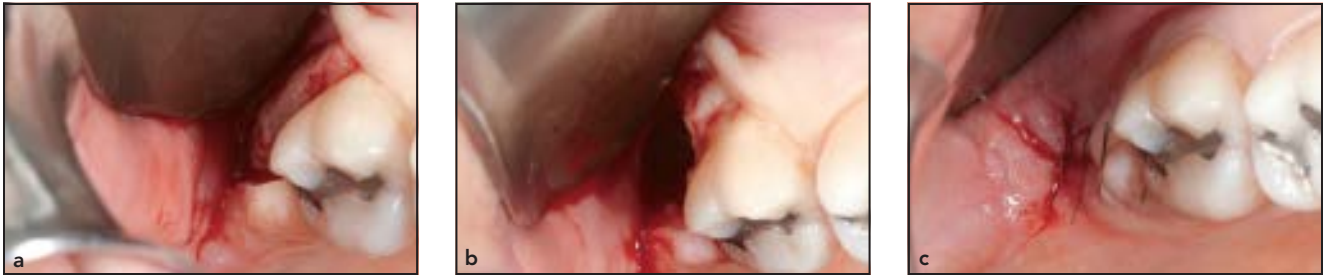


Fig 5 (a) The right tuberosity was accessed, (b) the bone graft was removed, and (c) the donor region was sutured (patient 1).

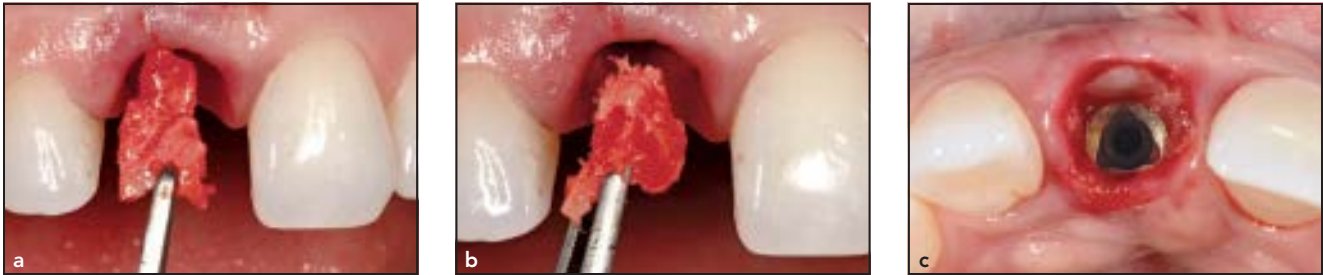

Fig 6 (a) After reshaping to match the bone defect, the corticancellous graft was inserted in the receptor site and (b) particulate cancellous bone was inserted until (c) it completely filled the remaining gaps between the corticancellous graft and the implant (patient 1).

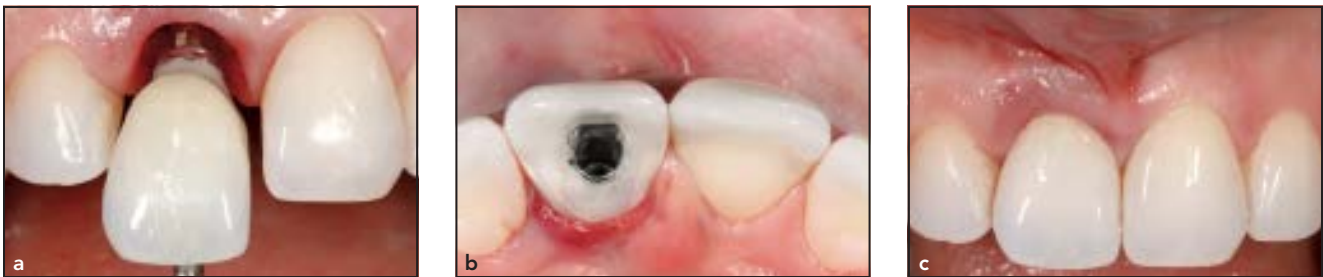

Fig 7 (a) The provisional crown was immediately placed. A concave contour was produced in the cervical portion of the provisional crown to better accommodate the tissue while (b and c) providing marginal sealing (patient 1).

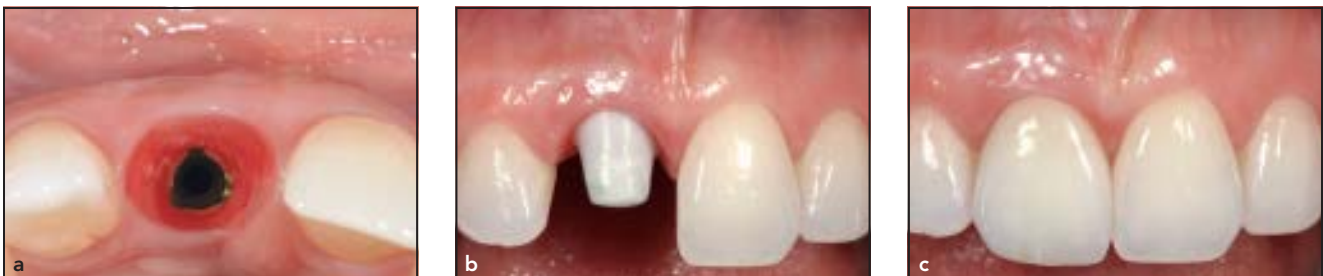

Fig 8 (a) Soft tissue response 6 months later. (b) The customized zirconia abutment and (c) the porcelain crown were delivered (patient 1).

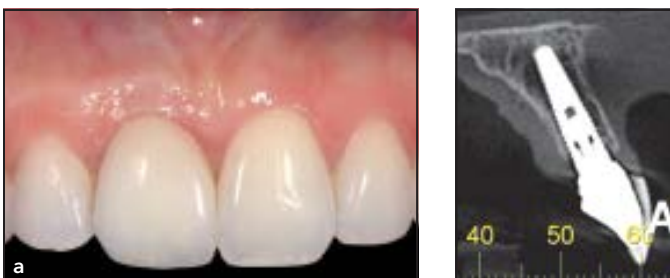


Fig 9 (a) Clinical control during the follow-up assessment. (b) Tomographic slices showing the buccal bone wall after the follow-up period (patient 1).

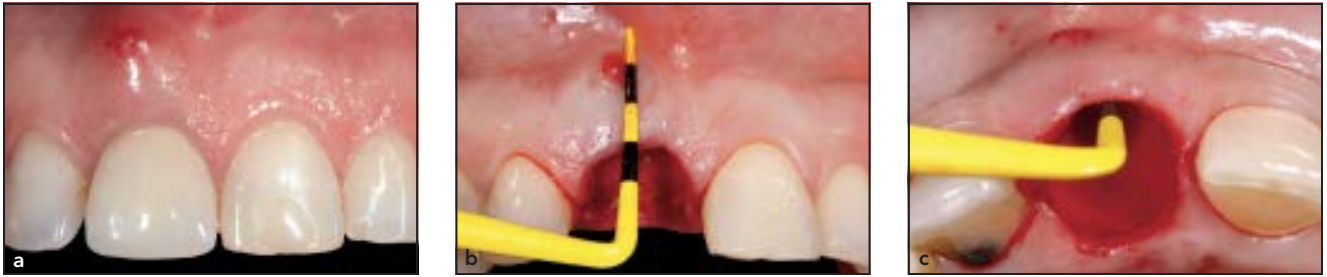

Fig 10 (a) Initial clinical assessment of the compromised right central incisor. (b) Absence of the buccal bone wall was confirmed after dental extraction. (c) Measurement of the degree of alveolar bone loss by probing the socket walls (patient 2).

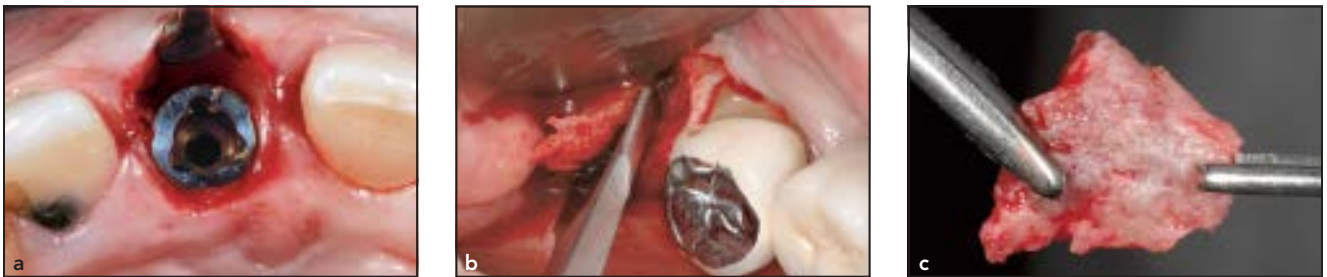

Fig 11 (a) After implant placement with palatal wall anchoring, the bone defect was evaluated again to facilitate appropriate chisel selection. (b) Bone graft being harvested from the maxillary tuberosity using a gouge chisel. (c) Modeling of the corticocancellous bone graft, which was shaped to match the defect configuration using a rongeur (patient 2).

Fig 12 (a) The corticocancellous graft was inserted and stabilized by juxtaposition, and (b) particulate cancellous bone was packed between the medullary portion of the graft and the surface of the implant (patient 2).

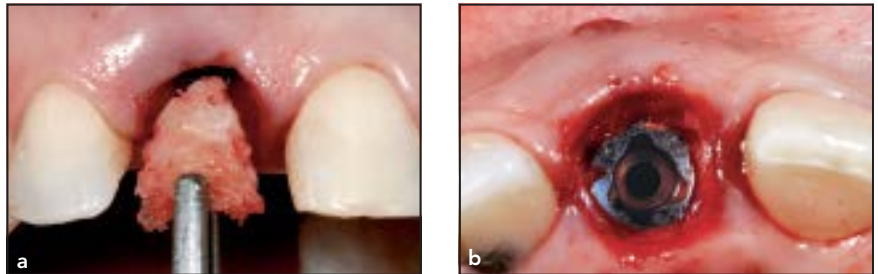


Fig 13 (a) Healing of the soft tissues when the provisional crown was removed. (b) The definitive porcelain crown was fabricated over the implant, and composite resin restorations were performed in the neighboring teeth (patient 2).

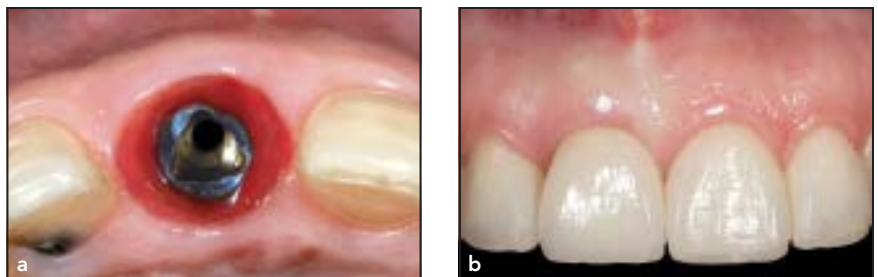

Fig 14 (a) Clinical control showing stabilization of the soft tissue. (b) Tomographic slice showing restoration of the buccal bone after the follow-up period (patient 2).

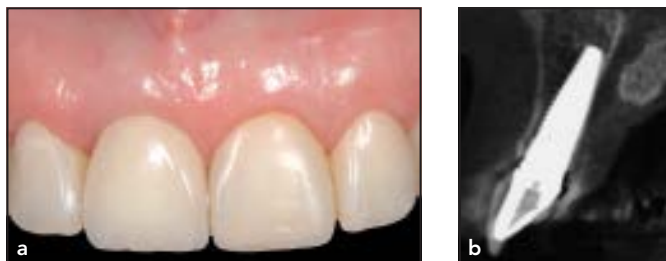

Table 2 Peri-implant soft tissue dimensions at baseline and follow-up (mean \pm SD)

	Baseline (mm)	Follow-up (mm)	P
Crown height	12.85 \pm 2.33	12.79 \pm 2.48	.546
MPL	4.34 \pm 1.31	4.54 \pm 1.41	.045
DPL	3.60 \pm 0.76	3.90 \pm 0.95	.041

MPL = mesial papillary height; DPL = distal papillary height.

Discussion

The main goal of this study was to determine the long-term stability of the soft tissue contour in the esthetic zone when the IDR technique is used for an immediate implant in a compromised fresh socket. The goal of the IDR technique is to reestablish the facial bone wall, thereby correcting socket defects and supporting the esthetic soft tissue with a bone graft from the maxillary tuberosity. A buccal bone wall of sufficient dimensions is a prerequisite for esthetic soft tissue contours on the facial aspect.^{1,2,7,19} The present prospective case series with 18 consecutive patients provides additional evidence that immediate implant placement into a compromised fresh socket for single tooth replacement in the esthetic zone offers successful treatment outcomes, with high predictability and a low complication rate. During the 58.56 \pm 8.19 months of follow-up, all 18 implants achieved and maintained successful tissue integration, as documented by clinical and gingivomorphometry parameters.

The predictability of immediate implant placement in postextraction sites has been demonstrated by various clinical studies according to previously established success criteria.^{1,2,9,20} However, few studies have objectively described the long-term esthetics of the soft tissue. The preservation or creation of harmonious soft tissue contours of the peri-implant mucosa may be the most important factor for achieving favorable esthetic results after implant treatment in the esthetic zone.^{7,21-24} In the present study, the esthetic outcomes on the facial aspect demonstrated a minor mucosal recession of 0.06 mm, which confirms the predictable outcome of the IDR technique.

Most gingival recession is observed within 6 months of soft tissue and implant surgeries.^{2,25} In addition, a thin gingival biotype represents an inherent risk of recession. However, these results showed a low risk for advanced recession after immediate implant placement in a compromised fresh socket, despite the gingival biotype, compared with three controlled clinical studies.^{3,26} In addition to the small

number of patients evaluated, this result may be influenced by the anatomical contour of the emergence profile used in the developmental phase of the implant restorations. As a result, more space may have been left for the surrounding tissues, thereby reducing the risk of soft tissue recession.

In addition to recession, the papillary height is an important soft tissue parameter for the esthetic²⁵ outcome, and it has gained increasing attention in recent years. In the present study, the mean MPL and DPL values increased slightly over time, indicating that the papilla height increased to a certain extent around the definitive restorations. To achieve a correct mucosal level on the facial aspect, the following two prerequisites must be fulfilled: the implant must be correctly positioned in 3D in the buccolingual and coronal directions, and the mucosa must be supported by a facial bone wall of sufficient height and thickness.⁸ The papilla levels of an anterior single implant may also be dictated by the proximal bone levels of the adjacent teeth. Studies^{1,8} have suggested that papilla-sparing incisions could minimize interproximal bone loss, thereby minimizing papillary loss. Thus, implant treatment goals must include the reconstruction of these lost structures.

Many clinical studies^{1,2,6} have reported the use of bone block grafting, biomaterials associated with GBR, and other techniques for the reconstruction of the facial bone wall. However, in the present study, the autogenous bone from

the maxillary tuberosity was chosen to correct the socket defects. This choice has several advantages. The graft repair is enhanced because the periosteal cells of the maxillary tuberosity act as osteoprogenitor cells. The graft is easy to harvest and adapts to the receptor region due to the bone malleability. In addition to restoring the lost vestibular bone plate, the corticocancellous bone sliver impedes cell competition between the hard and soft tissues, thereby promoting effective bone and gingival healing.¹³ The vascularization pattern is vital for bone grafting success. The trabecular nature of grafts harvested from the maxillary tuberosity suggests that such grafts have high revascularization capacity and release growth factors to the receptor site.²⁸ Hence, these grafts need to be transported rapidly to prevent the loss of their fundamental properties.²⁹ However, the maxillary tuberosity also has some disadvantages, including the limited quantity of bone available and difficulty of surgical access.³⁰

Conclusion

This prospective case series demonstrated stable peri-implant soft tissue levels over a 58-month period after single implant treatment in the esthetic zone using the IDR technique for immediate implants in compromised fresh sockets. Therefore, this technique may be considered a valuable and predictable option for the placement of implants in the esthetic zone.

Acknowledgments

The authors reported no conflicts of interest related to this study.

References

- Buser D, Chappuis V, Bornstein MM, Wittneben JG, Frei M, Belser UC. Long-term stability of contour augmentation with early implant placement following single tooth extraction in the esthetic zone: a prospective, cross-sectional study in 41 patients with a 5- to 9-year follow-up. *J Periodontol* 2013;84:1517–1527.
- Cosyn J, Eghbali A, De Bruyn H, Collys K, Cleymaet R, De Rouck T. Immediate single-tooth implants in the anterior maxilla: 3-year results of a case series on hard and soft tissue response and aesthetics. *J Clin Periodontol* 2011;38:746–753.
- Luo Z, Zeng R, Chen Z. Single implants in the esthetic zone: Analysis of recent peri-implant soft tissue alterations and patient satisfaction: A photographic study. *Int J Oral Maxillofac Implants* 2011;26:578–586.
- Hürzeler MB, Von Mohrenschildt S, Zuhr O. Stage-two implant surgery in the esthetic zone: A new technique. *Int J Periodontics Restorative Dent* 2010;30:187–193.
- Steigmann M, Salama M, Wang HL. Periosteal pocket flap for horizontal bone regeneration: A case series. *Int J Periodontics Restorative Dent* 2012;32:311–320.
- Pieri F, Aldini NN, Marchetti C, Corinaldesi G. Esthetic outcome and tissue stability of maxillary anterior single-tooth implants following reconstruction with mandibular block grafts: A 5-year prospective study. *Int J Oral Maxillofac Implants* 2013;28:270–280.
- Noelken R, Neffe BA, Kunkel M, Wagner W. Maintenance of marginal bone support and soft tissue esthetics at immediately provisionalized OsseoSpeed implants placed into extraction sites: 2-year results [epub ahead of print]. *Clin Oral Implants Res* 2013 Jan 14.
- Cosyn J, Sabzevar MM, De Bruyn H. Predictors of inter-proximal and midfacial recession following single implant treatment in the anterior maxilla: A multivariate analysis. *J Clin Periodontol* 2012;39:895–903.
- Belser UC, Med P, Bruno D, Higginbottom DM, Buser D, Dent PM. Outcome analysis of implant restorations located in the anterior maxilla: A review of the recent literature. *Int J Oral Maxillofac Implants* 2004;19(suppl):30–42.
- Den Hartog L, Raghoobar GM, Stellingsma K, Vissink A, Meijer HJA. Immediate non-occlusal loading of single implants in the aesthetic zone: A randomized clinical trial. *J Clin Periodontol* 2011;38:186–194.
- Meijndert L, Meijer HJ, Stellingsma K, Stegenga B, Raghoobar GM. Evaluation of aesthetics of implant-supported single-tooth replacements using different bone augmentation procedures: A prospective randomized clinical study. *Clin Oral Implants Res* 2007;18:715–719.
- Malchiodi L, Cucchi A, Ghensi P, Nocini PF. Evaluation of the esthetic results of 64 nonfunctional immediately loaded postextraction implants in the maxilla: Correlation between interproximal alveolar crest and soft tissues at 3 years of follow-up. *Clin Implant Dent Relat Res* 2013;15:130–142.
- Corbella S, Taschieri S, Samaranayake L, Tsesis I, Nemcovsky C, Del Fabbro M. Implant treatment choice after extraction of a vertically fractured tooth. A proposal for a clinical classification of bony defects based on a systematic review of literature [epub ahead of print]. *Clin Oral Implants Res* 2013 Apr 8.
- Kan JY, Rungcharassaeng MS, Lozada JL, Zimmerman DD. Facial gingival tissue stability following immediate placement and provisionalization of maxillary anterior single implants: A 2- to 8-year follow-up. *Int J Oral Maxillofac Implants* 2010;26:179–88.
- Rosa JC, Rosa DM, Zardo CM, Rosa AC, Canullo L. Immediate dentoalveolar restoration with platform switching, implant placement and bone grafting in the postextraction site. *Implant News* 2009;6:551–558.
- Rosa JC, Rosa AC, Rosa DM, Zardo CM. Immediate dentoalveolar restoration of compromised sockets: A novel technique. *Eur J Esthet Dent* 2013;8:432–443.
- Buser D, Martin W, Belser UC. Optimizing esthetics for implant restorations in the anterior maxilla: Anatomic and surgical considerations. *Int J Oral Maxillofac Implants* 2004;19(suppl):43–61.

18. Weinländer M, Lekovic V, Spadijer-Gostovic S, Milicic B, Krennmaier G, Plenk H. Gingivomorphometry: Esthetic evaluation of the crown-mucogingival complex: A new method for collection and measurement of standardized and reproducible data in oral photography. *Clin Oral Implants Res* 2009;20:526–530.
19. Lin CD, Chang SS, Liou CS, Dong DR, Fu E. Management of interdental papillae loss with forced eruption, immediate implantation, and root-form pontic. *J Periodontol* 2006;77:135–141.
20. Dierens M, De Bruecker E, Vandeweghe S, Kisch J, De Bruyn H, Cosyn J. Alterations in soft tissue levels and aesthetics over a 16-22year period following single implant treatment in periodontally-healthy patients: A retrospective case series. *J Clin Periodontol* 2013;40:311–318.
21. Fagan MC, Owens H, Smaha J, Kao RT. Simultaneous hard and soft tissue augmentation for implants in the esthetic zone: Report of 37 consecutive cases. *J Periodontol* 2008;79:1782–1788.
22. Huynh-Ba G, Pjetursson BE, Sanz M, et al. Analysis of the socket bone wall dimensions in the upper maxilla in relation to immediate implant placement. *Clin Oral Implants Res* 2010;21:37–42.
23. Lee YM, Kim DY, Kim JY, et al. Peri-implant soft tissue level secondary to a connective tissue graft in conjunction with immediate implant placement: A 2-year follow-up report of 11 consecutive cases. *Int J Periodontics Restorative Dent* 2012;32:213–222.
24. Knoernschild KL. Early survival of single-tooth implants in the esthetic zone may be predictable despite timing of implant placement or loading. *JEBDP* 2012;12 (3, suppl):209–212.
25. De Rouck T, Collays K, Cosyn J. Immediate single-tooth implants in the anterior maxilla: A 1-year case cohort study on hard and soft tissue response. *J Clin Periodontol* 2008;35:649–657.
26. Van Kesteren CJ, Schoolfield J, West J, Oates T. A prospective randomized clinical study of changes in soft tissue position following immediate and delayed implant placement. *Int J Oral Maxillofac Implants* 2010;25:562–570.
27. Palattella P, Torsello F, Cordaro L. Two-year prospective clinical comparison of immediate replacement vs immediate restoration of single tooth in the esthetic zone. *Clin Oral Implants Res* 2008;19:1148–1153.
28. Cicconetti A, Sacchetti B, Bartoli A, et al. Human maxillary tuberosity and jaw periosteum as sources of osteoprogenitor cells for tissue engineering. *Oral Surg Oral Med Oral Pathol Oral Radiol Endod* 2007;104:618.
29. Prolo DJ, Rodrigo JJ. Contemporary bone graft physiology and surgery. *Clin Orthop Relat Res* 1985;(200):322–342.
30. Goldberg VM, Stevenson S. Natural history of autografts and allografts. *Clin Orthop Relat Res* 1987;(225):7–16.